

COLUMBIA LIBRARIES OFFSITE
HEALTH SCIENCES STANDARD



HX64117065

RC202 .C36


The sequelae of gono

RECAP



THE LIBRARIES
COLUMBIA UNIVERSITY

HEALTH SCIENCES
LIBRARY
GIFT OF
RHODE ISLAND MEDICAL
SOCIETY



Digitized by the Internet Archive
in 2010 with funding from
Open Knowledge Commons

FISKE FUND PRIZE DISSERTATION. No. XLVIII.

THE SEQUELAE OF GONORRHEA

IN

BOTH SEXES.

MOTTO :

“ The Way of Transgressors is Hard.”

Proverbs, xiii, 15.

BY

W. LOUIS CHAPMAN, M. D.

PROVIDENCE, R. I.

RC 202

C36

Columbia University
in the City of New York

College of Physicians and Surgeons

Library



GIFT OF

RHODE ISLAND MEDICAL SOCIETY

THE SEQUELAE OF GONORRHEA

IN

BOTH SEXES.

MOTTO:

“The Way of Transgressors is Hard.”

Proverbs, xiii, 15.

BY

W. LOUIS CHAPMAN, M. D.

PROVIDENCE, R. I.

PROVIDENCE:
SNOW & FARNHAM, PRINTERS,
1905.

RC 202

C 36

THE Trustees of the Fiske Fund, at the annual meeting of the Rhode Island Medical Society, held at Providence, June 1, 1905, announced that they had awarded a premium of two hundred and fifty dollars to an essay on "The Sequelae of Gonorrhoea in Both Sexes," bearing the motto :

"The Way of Transgressors is Hard."

The author was found to be W. LOUIS CHAPMAN, M. D., of Providence, R. I.

CHRISTOPHER F. BARKER, M. D., Newport, R. I.,

CHARLES V. CHAPIN, M. D., Providence, R. I.,

FRANK B. FULLER, M. D., Pawtucket, R. I.,

Trustees.

HALSEY DE WOLF, M. D., Providence,

Secretary of the Trustees.

SYNOPSIS.

- I. **INTRODUCTORY.**—Etiology always complex—Normal bacteriology of the genitalia—The great frequency of gonorrhœa—its curability—The scope and significance of this essay.
- II. **BACTERIOLOGICAL CONSIDERATIONS.**—Cultural characteristics—Gonotoxin—Experimental inoculations—Reinfection—auto-reinfection—Immunity—Requirements for positive diagnosis—Blood cultures—The blood in gonorrhœal disease—Gonorrhœa in horses (original).
- III. **THE MECHANICS OF GONORRHEAL COMPLICATIONS.**—Paths of extension of infection—Natural barriers to extension—Instrumentation trauma—Experimental study of instrumentation trauma (original)—Ureteral catheterization—Traumatic agencies in operations on the female genitalia—Experimental studies on silver nitrate and corrosive sublimate to determine possible cause of stricture and ulceration.
Latent Gonorrhœa, anatomy of—Illustrative cases.
- IV. **SEQUELAE COMMON TO BOTH SEXES.**
Affections of the Eye.—Avenues of infection—Ophthalmia—Experiments with toxin, causing blindness, pathology.
Iritis.
Iridochoroiditis.
Panophthalmitis.
Causing Ear Disease.
Stomatitis.—Gross and minute pathology—Gingivitis.
Arthritis.—Pathology—Clinical features.
Periostitis.—Cases.
Myositis.—Pathology.
Abscess and Phlegmon.
Cystitis.—Of the male—Of the female—Causes and pathology.
Nephritis.—Anatomical approaches—Pyonephrosis and perinephritic abscess.

Of Rectum.—Pathology—Cases.

Skin Diseases.—Eczema—Phagadenic ulcers—Maculae gonorrhoeicae—Pruritus—Erythemata—Dactylitis.

Diseases of the Nervous System.—Neuralgia—Neuritis—Muscular atrophy—Meningitis.

Neurasthenia.

Pleurisy.

Pneumonia.—Pathology and cases.

Endocarditis and Myocarditis.—Pathology—Cases.

Phlebitis and Arteritis.

General Systemic Invasion.—Sources—Pathology—Cases—Recovery possible.

V. SEQUELAE PECULIAR TO THE MALE.

Prostatic Involvement.—Anatomical limitations of suppurative process—Pathology—Abscess—Predisposing to hypertrophy—Phlebitis of prostatic plexus.

Epididymitis—Orchitis—Vesiculitis (original).—Pathology—Anatomical limitations—Sequelae of these.

Balanitis—Cowperitis, etc.

Sterility in the Male.

Peritonitis in the Male.—Cases.

VI. SEQUELAE PECULIAR TO THE FEMALE.

Vaginitis.—Pathology—Xerosis and atresia.

Bartholinitis—Skene's Glands.

Stricture Urethrae.

Endometritis—Perimetritis—Pelvic Abscess.

Ovaritis.—Pathology.

Salpingitis.—Pathology (original)—Of infants—Cases.

Sterility.—Of female.

Complicating Pregnancy and the Puerperium.—Anatomical and mechanical features—Puerperal fever—Causing abortion.

Peritonitis.—Predisposing factors—Approaches—Question of operation in gonorrhoeal cases—Cases—Comparison with streptococcus infections—Differential diagnosis.

VII. CONCLUSIONS.—Is gonorrhoea a predisposing factor in genito-urinary tuberculosis and neoplasms?

Exhibit of Photomicrographs.

PREFACE.

IT will at once be evident that this essay is a work of compilation and investigation. Of compilation,—because most of our knowledge is but recently acquired and is to be found only in very recent research monographs and case reports. Of investigation,—because the writer presents herewith the results of original work on the mechanical effects of traumatism, the pathology of gonorrhœal salpingitis, prostatitis and seminal vesiculitis, and the comparative effects of silver and mercury salts.

The writer wishes to acknowledge his obligation to Dr. Tolles, Assistant Pathologist to the Rhode Island Hospital, for valuable pathological material.

I.

THE SEQUELAE OF GONORRHEA IN BOTH SEXES.

THROUGH the recent studies of Adami (Jn. Am. Med. Assn. xxxiii, 1500), Ford (Trans. Assn. Am. Phys. xv, 398), Nichols (Jnl. Med. Res. xl, No. 2), and others, who found that both pathogenic and saphrophytic bacteria were occasionally found in apparently normal tissues, an additional duty has been imposed on students of the causes of pathological conditions. Before determining the cause of a bacterial disease it is first necessary to inquire into what may be termed the normal bacteriology of the part. This is of particular importance in any inquiry into bacterial disease of the genito-urinary organs of either sex. Through the researches of Kronig, Bumm, Doléris, Martin, Schroeder, Winter and His, we know that the uterus, vagina and urethra contain a variety of bacteria: Asakura (Zeit. f. d. Krank. der Harn. xvi, Heft iii) has found streptococci in the urethras of 14 out of 112 healthy men. Thus, at the outset of this study, it is evident that it is not at all easy to ascribe conditions to the gonococcus alone, that many of the complications of gonorrhoea are due to a mixed infection, and that some of our most suggestive and important cases are contributions to the bacteriology of other species also.

That gonorrhoeal urethritis is a very common and widespread disease cannot be questioned. But it cannot be justly claimed that the percentage of cases in

males is as high as is often asserted, and the writer would take issue with all statements of 70%, 80% and 90% of all males in large cities being or having been infected. (Johnson, *Am. J. Obst.* Feb. 1904.) The writer has been unable to find proof of any such figures. But few statistics will bear criticism, and only those from reliable sources will be offered in this essay. In the Heidelberg obstetrical clinic 27% of 108 pregnant women had gonorrhœa. In Zweifel's private practise, but 11% of his patients had the disease. In 1930 gynecological cases Sanger found but 230 cases of gonorrhœa and of 1617 pregnant women Schwartz found clinical gonorrhœa in but 77. The committee appointed by the American Medical Association to investigate the status of gonorrhœa as a cause of surgical diseases of women, have concluded that of all pelvic disorders requiring operation, 40% are due to gonorrhœa. Figures such as these, well supported by records, are sufficient to disprove the extravagant statements so often made in current literature.

It is no easy matter to discuss the question of the curability or incurability of acute and chronic gonorrhœal urethritis, upon which the development of complications so much depends. Many pages might be devoted to this subject, but for brevity it may be stated that the following are the chief reasons for the extreme chronicity of the primary disease:—non-professional treatment: absence of treatment until complications appear: alcoholism and venery during the course of the disease: unscientific treatment: the cultural characteristics of the gonococcus: the anatomical by-paths inaccessible to medicaments: and the

various concomitants of venereal disease. Many other features will be apparent in various parts of this work.

Although it is clearly beyond the scope of this paper to discuss methods of treatment, it is of the greatest importance to note the progressive trend of therapeutics and prophylaxis. Recent additions to the medical and surgical armamentaria, together with the dissemination of popular knowledge of the hygiene of venereal cases, have not only contributed in an immeasurable degree to the curability of gonorrhœa but have greatly inhibited its spread and prevented systemic complications. For example, — caustic and irritating injections are now rarely used, preference being given to recently devised silver salts; divulsion of the urethra has largely given place to internal urethrotomy; patients are now told of the communicability of the disease and urged to co-operate with the physician in his efforts to bring about a complete cure. These are but a few of the newer ideas in treatment, upon which so much depends as regards complications. In proof of the efficiency of modern methods witness the accounts of epidemic ophthalmia neonatorum with its wholesale destruction of eyesight recorded in early writings; and the experience of Fuchs who found that for every 100 patients with gonorrhœa neonatorum, 15 nurses acquired ophthalmia.

In opposition to the time-honored view, once infected always infected, attention should be called to the many cases, known to every practitioner, of gonorrhœa which go on to complete resolution in one or two months, which are followed by no sequelae whatever, and later marriage of the infected party is

followed by healthy offspring with no involvement of the maternal genitalia. The great difficulty of compiling statistics on this aspect of the subject is at once apparent.

In an investigation such as this the sociologist will find information regarding the variety of complications possible in gonorrhoea, of value in the ever-increasing efforts designed to bring people to a keener realization of social evils. To the popular mind there is no more cogent argument than plain exposition of cause and effect, and a propaganda based on a more complete knowledge of this disease, with the suppression of the many false ideas still prevalent regarding its transmission and curability, will do much towards diminishing its frequency.

The economist will find the influence of this disease on reproductivity an important factor in the study of pauperism, crime, indigence and race suicide.

The student of scientific medicine will find an exposition of the forces underlying the complications and sequelae of gonorrhoea and cases of gonorrhoeal infection which duplicate nearly all varieties of clinical phenomena caused by other pathogenic bacteria.

II.

BACTERIOLOGICAL CONSIDERATIONS.

IN order to appreciate the functions of the gonococcus and to understand its effects on the human organism, it is important to review the less well-known features of its biology and to cite representative examples of its pathogeny derived from experimentation.

The gonococcus differs in many particulars from nearly all other pathogenic bacteria,—in its cultivation, specific toxin, selective affinities and the lesions it causes, it is unique.

Cultivation.—It cannot be cultivated with the same ease as *B. typhosus*, *B. diphtheriae*, *B. coli com.*, streptococci and staphylococci, but grows best on solidified blood serum, blood agar, and Wertheim's medium. The latter consists of one part fluid serum, preferably human serum from the placenta or effusion of pleurisy or hydrocele, and two parts of liquified agar at 40° C. Multiplication best occurs at the body temperature and ceases at 25° C. Colonies appear soon after 24 hours in separate semi-transparent discs of undulate margin and irregularly rounded shape, reaching their maximum on the fourth day and usually dying out before the ninth day. Successive transplantations are usually unsuccessful, but Heiman has been able to keep the gonococcus alive in culture

media for as long a time as 82 days and has transplanted as many as 25 times. The generally accepted view that this organism does not grow on other media is disputed by Schonk, Urbon and Wildholz (Deut. med. Woch. Mch. 3, 1904), who have successfully cultivated it on ascitic fluid, glycerine agar, bouillon, gelatine and glucose agar and horse serum. These observers suggest the possibility of a closer relation between the gonococcus and the diplococcus intracellularis meningitidis of Weichselbaum, on account of these cultural characteristics. Until more evidence is available, however, we must consider the latter as a distinct species, and in the discussion of gonorrheal affections of the nervous system, disorders caused by it will be omitted.

According to Sternberg the gonococcus is killed by 60° C in 10 minutes and by experimentation Rudis-Jicinsky (N. Y. Med. J. 1901, lxxiii, 364) has found that it is killed by the X-rays in 35 minutes if in an acid medium and in 40 minutes if in alkaline.

Young (Jhns. Hopk. Hospt. Rpts. ix, 684) reports an interesting observation in which gonorrheal fluid aspirated from a wrist joint showed, after a long search, but two leucocytes each containing two gonococci. After 36 hours incubation in ascitic agar, great numbers of leucocytes filled with gonococci, some containing as many as 400 could be readily seen. This interesting and unusual observation illustrates the rapid multiplication of the gonococcus and also the fact that the leucocytes are ready to take them up even in artificial media.

Experiments made by Wertheim (Arch. f. Geb. u. Gyn. 1902, xlii, 192) and verified by a number of

others are of both scientific and sociological significance. Obtaining a pure culture of gonococci from a man with gleet of two years duration he attempted reinfection of the original urethra but always failed. When inoculated into a normal urethra, typical acute gonorrhoeal urethritis was produced. Material from this urethritis transplanted into the original urethra caused a fresh gonorrhoea, which, after running a typical six weeks' course, subsided into the chronic gleet formerly existing.

For absolutely positive diagnosis, three conditions must be satisfied, — the morphology, staining reactions and cultural characteristics. In doubtful cases of interest and in those of medico-legal importance all three of these features must be noted. It is not only necessary to find the characteristic biscuit-shaped cocci, arranged in pairs and within the margin of the leucocytes, staining with all basic aniline stains and completely decolorising by Gram's method, it is also to be plated out by Wertheim's method, and must show typical colonies from which the gonococcus can be reclaimed. In staining smears portions of a culture of *staphylococcus aureus* may be placed on the same slide for comparison.

Gonotoxin may be isolated, and experiment shows that it alone may cause inflammation and destruction of tissue. It is found that the toxin varies in strength under different conditions, as do cultures, that cultures sterilized by heat may be as injurious to animals as the living organisms, and that animals which are not susceptible to the organism itself may be affected by the toxin.

DeChristmas (Ann. de l'Inst. Past. xiv, 331, 609) employed a mixture of one part ascitic fluid and three parts bouillon for a medium. Twelve days growth must take place before the culture has toxic properties, and then most of the organisms are dead, the toxin evidently being formed by the disintegration of their bodies. The toxin is precipitated with other proteids by absolute alcohol, is soluble in glycerine, is albuminoid in character, is not dialyzable, resists 60° C. for one hour, but is changed by 75° C. in 15 minutes.

Randolph (Am. J. Med. Sci. Nov. 1902) has verified the studies of deChristmas and Schaefer and has obtained a toxin from the filtrate of a gonococcus culture in agar with two parts of plain sugar and one of hydrocele fluid. An eight days growth was covered with chloroform for twelve hours, it was then scraped off and mixed with sterile water or bouillon. His experiments with the toxin will be referred to in the discussion of gonorrhoeal affections of the eye.

A satisfactory anti-gonotoxin has not yet been elaborated.

Inoculations.—The injection of pure cultures into the peritoneum of white mice causes localized purulent peritonitis with penetration of the subendothelial connective tissue, but the organisms do not thrive and the inflammation soon subsides. Injected into the joints of rabbits, guinea-pigs and dogs an acute inflammation is produced which soon dies out,—showing conclusively that in these animals the gonococcus has no enduring power and that they have a partial immunity. Inoculation of pure cultures and gonorrhoea

pus into the urethras of animals are negative and do not reproduce the disease.

The subcutaneous injection of 2 cc. of sterilized culture into rabbits causes inflammation and infiltration which soon continues to necrosis. The injection of 10 cc. of the same toxin causes local phlegmonous inflammation, the animal becomes sick, loses its appetite, and dies of chronic marasmus. Injected into the brains of guinea-pigs, spastic and paralytic phenomena and death in 16 hours are caused.

The injection of 0.1 cc. into the human subject causes pain at the site of injection, chills and evening elevation of temperature to 38° C. At night there is pain in the joints and headache. For two days there was pain and swelling at the point of injection, but these gradually disappeared. (Wassermann, *Cent. f. Bakt.* 1897.) This material has been used clinically with the view of mitigating symptoms, but no curative effects whatever were observed; on the contrary, the symptoms were aggravated. In order to learn if the toxin alone was capable of causing a blenorrhagic discharge, Wassermann introduced it into a normal male urethra, and, after the lapse of a few days, pronounced suppuration ensued. Similar experiments with the toxins of other pathogenic bacteria were negative, which would seem to show that the urethra is quite tolerant of the toxins of other bacteria, but has a specific reaction with the gonococcus or its toxin.

A partial immunity to the gonococcus may be acquired, but is never natural or congenital. Indeed, there is a slight natural immunity with advancing years, infants being very susceptible to gonorrhoeal invasions, most cases occurring before the age of

thirty, and a very much smaller number later in life. In experimentation on animals deChristmas found an increasing immunity with successive inoculations, and in the human being there is an acquired partial immunity, varying with the course of the infection but never complete. The difficulty of distinguishing between a new infection and an acute exacerbation of a latent or uncured disease, makes clinical evidence of but little importance in determining the immunity acquired by successive gonorrhoeal infections. It has been observed, however, at the San Salvador Hospital (Cent. f. Gyn. 1901, No. 3), where a large number of cases of gonorrhoea in women are treated annually, that reinfection of those cured in the hospital rarely occurs.

As to the variability in virulence of the gonococcus and the effect of its association with other organisms, we have as yet but little accurate information. Clinical experience shows that in apparently normal and similar persons the coccus causes widely different phenomena, varying from a slight catarrh with prompt resolution to intense and progressive inflammation with many and varied sequelae. Although it is readily proved that in the cultivation of the gonococcus in artificial media the virulency decreases with successive generations, the opposite seems to be true when the germs are incubated in human tissues, and that old cases may furnish toxins and cocci of a very high grade of virulence. The pregnant state seems to offer particularly favorable conditions for the development of the gonococcus, although we are as yet unable to state why on account of our imperfect knowledge of the biochemical conditions of pregnancy.

Blood Cultures should be taken oftener and would undoubtedly reveal a much larger number of positive findings than would be supposed. Krause points out that they should be made immediately upon the appearance of any rise in temperature during a gonorrhoeal infection, and that 20 cc. to 40 cc. must be taken. This is to be mixed with glycerine serum agar, cooled to 40° C. and incubated at 37.6° C., or with Latimer's fluid, which consists of ascitic fluid mixed with equal parts of bouillon, 1% peptone and .5% Na Cl. The search for colonies must be thorough, as they are often smaller than the head of a pin.

Hematology of Gonorrhoeal Infections. — Aside from the finding of the gonococcus in the blood, there is but little to distinguish gonorrhoea from other infections. There is moderate leucocytosis, the eosinophiles range from .5% to 11.5%; but Bettmann has observed them as high as 25% in a case of gonorrhoeal epididymitis. The blood changes in gonorrhoeal rheumatism are the same as those of idiopathic joint affections.

Dutzmann, who studied the blood in 165 cases of pelvic suppuration (Cent. f. Gyn. 1903, No. 47), concludes that a leucocytosis of 11,000 to 13,000 points to a gonorrhoeal, while upwards of 30,000 is indicative of streptococcus infection.

Although not strictly within the scope of this paper, the writer offers brief observations on two cases of gonorrhoea in mares, one a case of bestiality, the other caused by dilatation of the cervix by infected instruments. The former case was verified by bacteriological examination by Professor F. P. Gorham, the eminent bacteriologist of Brown University, to whom I

am indebted for the privilege of reporting the case. The profuse vaginal and urethral discharge began about three weeks after infection and rapidly proceeded into a severe and intractable cystitis. The latter case, although not examined bacteriologically, presented the following significant train of symptoms: after three days of general depression and malaise, a purulent discharge appeared at the vulva; physical examination showed intense inflammation of the vagina and urethra; the cervix uteri was a spongy rotten mass and was dimpled in stellate form, although the mare had never had a colt. With these there was great pain on urination, the bladder was in a high state of inflammation and cast off large amounts of pus. Nausea and vomiting were persistent. The acute stage lasted about 10 days and gradually subsided, the bladder and urethra being well in 14 days, but the muco-purulent vaginal discharge continued for three months.

The writer is unable to find other cases of gonorrhoea in animals in literature.

III.

THE MECHANISM OF GONORRHEAL COMPLICATIONS.

UNDER this heading the writer invites attention to those factors which directly predispose to complications, the channels by which infection proceeds from the urethra, paths other than the urethral whereby the gonococcus may gain admission to the system, and the mechanical or traumatic forces which further gonorrhoeal processes and open up hitherto uninvaded parts. While it is true that urethritis is not always of gonorrhoeal origin,—that Pezzoli and van der Pluym have found the colon bacillus, Legrain the *B. Typhosus*, and others that a variety of bacteria may cause purulent urethritis,—the fact remains that nearly all cases of urethritis are gonorrhoeal and show the coccus at some time in the course of the disease.

Gonorrhoea extends first by continuity of tissue in a manner quite analogous to bacterial diseases of the respiratory tract. Wherever there is continuity of epithelium the progress of inflammatory disease depends upon the nature and virulence of the infection, the specific susceptibility of the cellular elements, and the mechanical barriers which offer physical resistance. In the male genito-urinary organs, unbroken tracts may be traced from the urethra into the bladder, thence through the ureters to the kidneys; through the ducts into the seminal vesicles, vas and epididymis.

In the female the urinary tracts upwards from the urethra are substantially the same as the male, and the epithelium of the vagina continues with slight structural gradations into the uterus, tubes and peritoneum. What then are the chief forces which favor the spread of gonorrhoeal infection, what are the natural defences of the organism against its inroads, and what is the natural course of the disease uninfluenced by treatment?

Certain mechanical barriers are evident. Of very great importance in the preventing of ascending infection of the urinary tract is the downward flow of urine whereby infectious particles are washed out. The urethra, ureters, and seminal ducts are potential and not actual tubes, their walls being in apposition unless distended by outflowing fluids, a state which renders agglutination by mucous or inflammation easy and thus materially prevents the upward progress of bacteria. As to the form of the Fallopian tubes in this respect, the writer has made a large number of transverse sections to determine whether the tubes were normally collapsed or were actually tubular with a free and patent lumen. It appears that the latter is the case and that they have sufficient rigidity to prevent collapse and the apposition of mucous surfaces. This is a point of great importance as it is distinctly favorable to gonorrhoeal salpingitis. Sections of the seminal vesicles show that they also are patent and rigid tubes. The mucous plug which obstructs the cervix in the gravid uterus is a barrier of the greatest importance to the upward extension of gonorrhoea acquired during pregnancy.

Any cellular form may be invaded by the gono-

coccus, but it finds its most favorable soil in columnar epithelium and its next best habitat in the transitional form. In the female the epithelium of the vagina is thick and stratified; that of the uterus ciliated columnar; that of the cervix both cylindrical and columnar; the oviducts are lined with ciliated columnar epithelium; the urethra is paved with stratified transitional epithelium except at the internal orifice where it is stratified pavement. In the male the urethra, Cowper's glands, ejaculatory ducts, prostatic ducts, and epididymis have columnar epithelium and the vasa deferentia and seminal vesicles have stratified columnar. It is thus seen that the gonococcus does not everywhere find its favorite environment. There is no evidence that pavement forms exert any particular inhibitory action on the gonococcus or that it has any cytolytic affinity, but it seems probable that the squamous form of the cells, by their small amount of protoplasm and their dense compact manner of assemblage are mechanical rather than biological defences of the organism, and that they not only prevent extension along tubular tracts but also penetration into the tissues.

Effects of Instrumentation.

Instrumentation of the male urethra is performed largely for the relief of gonorrhoeal complications. The suppurating surface of the urethra in gonorrhoea is to be considered as protective against the deep involvement of the mucosa. Were this not so, glandular and periurethral complications would be frequent or universal instead of occasional. It is evident that anything which abrades the urethral epithelium or

denudes it of its protective hyperplasia, deprives it of its natural mechanical means of defence, affords a means of deeper seated bacterial infection and may drive bacteria into the tissues if force be used. Instruments do harm in two ways, — by the tissue damage they inflict and by the infection they may carry. If the urethra be over distended by the use of instruments of too great calibre, ruptures and minute hemorrhages result. If the point of the sound be forced, perforations or rupture of soft parts may occur. With some it has been the practice to dilate the urethra in acute and chronic urethritis, to iron out its wrinkles and folds that all parts might be bathed by injected medicaments. It has been found by many observers, however, that this was often productive of harm and that prostatic and periurethral complications were more frequent than when there was no instrumentation. The writer shares in the view that instrumentation of the suppurating urethra should be conducted with the greatest care, and that it is a dangerous procedure unless the tract is fairly free from pathogenic bacteria, — a thing which is absolutely impossible in the early stages of gonorrheal urethritis. In the instrumentation of any part invaded by the gonococcus it may be claimed that safety increases with lapse of time after inoculation, but that latency may exist after very long periods of time. Clinical realizations of the teaching that complications are often caused by instrumentation and traumatism are so frequent that it is not necessary to assemble cases. Whenever it is necessary to operate on the urethra it should be repeatedly cleansed with irrigating solutions by means of a soft retrojection catheter.

It has been argued that the use of injections of any kind renders involvement of the pars prostatica more probable. In the writer's opinion the great majority of cases of anterior urethritis become prostatic without any interference, and urethral injections without intra-urethral instrumentation do no harm unless the solution be irritating.

The traumatism of horseback or bicycle riding, blows on the perineum or excessive muscular exertion very frequently cause exacerbation of an acute or chronic gonorrhoeal urethritis, with immediate extension into the epididymis, prostate or inguinal glands. This is probably explained by the forcing of bacteria from the superficial layers of the urethra into the sub-mucous tissue, thereby starting a new inflammation and increasing the activity of the old. A similar condition may be noted in the female; infection may be resident in the vagina and urethra and the introduction of an infected sound be responsible for gonorrhoeal endometritis which promptly follows. Were instrumentation of the female urethra practised as often as that of the male, bladder involvement would be more frequent in women.

Experimental Study of Instrumentation Traumatism.

Failing to find accurate information in text-books, the writer has made observations on the amount of force necessary to cause tissue damage to the urethra, prostate, bladder and periurethral tissue. The ordinary instruments used in treatment and diagnosis were used,—sounds of correct curve, calibres from 2 to 32 F., Gouley's staff, wire stylets and filiform bougies.

The amount of force can be very accurately measured by scales attached to the instruments.

But little force is necessary to introduce a well-oiled sound into the normal urethra; often they will enter of their own weight and rarely is more than four ounces required. At the prostatic curve of the urethra, with proper guidance, four ounces is quite enough for an instrument of 20 F. calibre. With larger sounds one ounce more force may be required. But little force is required to puncture the membranous urethra. With small bougie or stylet four or six ounces may be enough, and with larger instruments a force of two pounds or more is almost sure to do damage. On the dissected prostate it is found that any force above four pounds is certain to penetrate the prostatic tissue. If the instrument be a stylet with either sharp, round or blunt point, penetration occurs with pressure of one pound or over. When one recollects that occasionally the stylet of silk catheters project from the eye, and that considerable force is often used, it is not surprising that false passages are occasionally made, that ducts are entered, and that suppurative processes are implanted.

When the urethra or prostate are once perforated; but very little force is required to continue on into the soft cellular tissue of the ischio-rectal fossa, the space of Retzius, or even the pelvic peritoneum.

The mucous membrane of the bladder is exceedingly delicate. Any force above one pound may be sufficient to cause rupture or separation from the muscular coat, to which it is bound by areolar tissue of exceedingly loose texture. Considerable force is required to puncture the bladder so resistant are its

tunics, which may resist a force of six pounds with a sound of only 8 F. Sharp-pointed instruments, however, easily penetrate when force of upwards of half a pound is exerted.

These figures represent averages of findings upon a number of individuals and upon normal organs. With pre-existing disease the force required to do damage would be much less. Inflamed and infiltrated urethras are very easily abraded and very gentle instrumentation is often followed by hemorrhage. Papillomata of the bladder are so delicate that even the passage of a soft catheter may be followed by bleeding and a sound or sharp-pointed instrument may cause hemorrhage which is controlled only by powerful astringents. From these experiments on the cadaver, in view of the very considerable force which we know is occasionally used in the instrumentation of the urethra, it seems remarkable that "urethral fever" and systemic infection are not of even greater frequency.

The recent introduction of ureteral catheterization as a means of diagnosis and treatment necessarily carries with it the greater opportunities for injury to the bladder, ureter and kidneys, as well as of transplanting infectious materials. The catheter might cause abrasions in the epithelium and imperfections in its surface might easily carry particles for deposition further up. Now, the very conditions for which ureteral catheterization are done are those which would afford abundant material for sepsis, and we find another application of the teaching already urged,—that of frequent washings of the bladder and urethra before catheterization of the ureters is done. The passage of urethral calculi may cause abrasions in which infectious

particles may lodge, as is illustrated by a case of gonorrhœal pyelitis of the writer's to be reported. Contusions of bladder and kidney regions and of the testicles favor gonorrhœal involvement by lowering tissue resistance and by hemorrhagic areas in which the gonococcus might become lodged.

Traumatic Agencies in the Female.—Among the important traumatic factors to which the female is subjected are those which would compress a gonorrhœal Fallopian tube and cause it to exude pus through its fimbriated end or to rupture. This trauma is usually due to one of the following classified circumstances:—

i. *Incident to Parturition at any Time in Pregnancy.*—Lacerations of the uterus, cervix, vagina and perineum, afford abundant opportunities for the ingress of bacteria, and are a very common cause of puerperal fever. With the increase in size of the gravid uterus the broad ligaments become tense, the abdominal wall is tightly stretched over the fundus and considerable pressure is exerted on the tubes, which is greater still if they be distended with pus. With the violent contractions of the uterus at term the compression must be very great, and it is not at all surprising that gonorrhœal peritonitis occasionally follows promptly after labor.

ii. *Operations on the Female Genitalia.*—Besides those already mentioned we have instrumental delivery, curetting of the uterus, dilatation of the cervix with instruments or tents, abdominal and pelvic operations of any kind upon tissues invaded by the gonococcus, and the transfer of gonorrhœal material from

the vagina to the rectum through faulty technique. Niebergall (Beit. zur Geb. u. Gyn. ii, Heft 1) reports two cases in which dilatation of the cervix for the relief of sterility was followed by pelvic gonorrhœa. The first, a woman of thirty-three, dilated with instruments which was followed in three days by a profuse discharge containing gonococci, with chills, high temperature, severe abdominal pains and the prompt development of pyosalpinx. The other, a woman of twenty-one, dilated with tents which caused the same sequence of symptoms.

iii. Accidental abdominal injuries which act in the same way as those already described.

In no disease, unless perhaps tuberculosis be excepted, is auto-reinfection so frequent as in gonorrhœa. In the male, the anterior urethra infects the urethra and the bladder; with improvement in the former the latter offers opportunity for new generations of gonococci and the process is perpetuated; the word is apt. In the female an infected tube distributes gonococci to the uterine cavity, the peritoneum, vagina and urethra, and upon one of these becoming free from inflammation and bacteria, the means of reinfection is at hand.

Brief Report of Experimental Study of Mercuric Chloride and Silver Nitrate.

The writer has observed a number of cases in which the use of injections of corrosive sublimate has been followed by stricture of the urethra, exacerbation of the urethritis, prostatitis and epididymitis. And, al-

though the discussion of stricture of the urethra is intentionally omitted from this paper for reasons already given, it seems quite germane to discuss one of its causes. In the first series of experiments solutions of corrosive sublimate were injected into the tissues of dogs, rabbits, guinea-pigs and frogs, and in all cases it was found that in any strength over $\frac{1}{5000}$ it immediately sets up a violent inflammatory reaction, thrombosis of all small vessels, perivasculitis, capillary rupture, and, if the injection is not followed by the death of the animal, a hard phlegmon develops at the site of the injection. That it causes increase in connective tissue appears from the photomicrograph taken of a section of the tongue of a frog into which a $\frac{1}{2000}$ solution had been injected. This is proven such by comparison with normal organs and by Mallory's connective tissue stain.

When introduced into the stomach of a frog a $\frac{1}{2000}$ solution causes death in about two weeks, the only symptoms observed being salivation, an occasional convulsion and progressive asthenia. The stomach is of a dark gray color and the intestines show the appearance of a violent enteritis. Sections show infiltration of the mucosa, in some places desquamation of the epithelium, and throughout the mucous membrane, and occasionally in the submucous tissue, there is evident a distinct increase in the normal connective tissue of the part. This finding also was verified by check observations and comparison with normal specimens.

Silver Nitrate. — A $\frac{1}{100}$ solution injected into the stomach of the frog causes but slight disturbance in the animal, — it seems uneasy, peristalsis is increased

and large quantities of mucous are expelled from the cloaca. The stomach is pale, anemic, and almost pure white in color, and contains a normal amount of secretion. There are no signs of irritation in the intestines. A solution ten times as strong causes intense discomfort and irritability on the part of the animal. There is great buccal irritation, profuse mucous discharge from the mouth and the expulsion of much mucous and epithelium from the cloaca. The stomach shows intense congestion; in some places there is complete desquamation of mucosa, but the inflammatory reaction is not as great as was surmised from the symptoms and behavior of the animal. The frog is not killed, but is sluggish in its movements and shows cutaneous argyria.

Frog killed, tissues killed in Zenker's, sectioned in celloidin, stained with Delafield's hematoxyline and Mallory's connective tissue-stain. But little change is observed in the stomach of frog into which the $\frac{1}{100}$ solution has been applied. The epithelium is for the most part unbroken and there is but little exudate. The gastric mucosa to which the 10% solution has been applied shows denudation of mucosa in places with the beginning of ulceration as illustrated in the photomicrograph. There is no increase of connective tissue.

Objections might be raised to the use of the stomach of the live frog for these experiments with silver nitrate, on account of the precipitation which occurs with chlorine in any form. The same thing, however, always occurs in the urethra, which is always in a state of salinity on account of the chlorides of the urine as well as of the urethral secretion. Indeed, it

is this property which prevents this chemical from causing lesions in clinical work.

In order to verify the teaching that the gonococcus particularly predisposes to the proliferation of connective tissue, the writer has examined a large number of sections from the prostate, urethra, tubes and ovaries in gonorrhoeal disease. He is unable to find in these any evidence that they contain more connective tissue than is usually found in conditions of acute and chronic inflammation caused by other organisms. It is a natural process for the walls of any suppurating sinus to contract, examples of which are found in the contraction and dimpling of healed abdominal sinuses, fecal fistulæ, ischio-rectal abscesses and the like. So, also, is it to be expected that the urethra, transformed in gonorrhoea into a suppurating sinus, would occasionally contract from the tissue changes which necessarily result in the healing of a deeply ulcerated surface. Did space permit the writer could offer a number of photomicrographs of gonorrhoeal tissues, which, by comparison with the normal of the organ affected, would readily show the validity of this argument.

Latent Gonorrhoea as a Cause of Complications.

This is one of the most important features in the production of gonorrhoeal sequelae. By latency a non-progressive focus of gonococci is meant and not a sub-acute gonorrhoea as is very frequently supposed. Anatomically this state is one of encystment, a group of cocci are surrounded by a capsule of connective tissue which is non-vascular, and no opportunities for nourishment and growth are afforded. With the dis-

turbance of such a nidus and the rupture of the capsule, together with focal hemorrhage such as very frequently accompanies even slight traumatism, the bacteria become active and at once begin their destructive work.

Instances in great number might be offered, but the following are of particular interest:— A man acquires gonorrhœal urethritis in his younger days but supposes himself cured. Seeking professional advice for prostatic disease at the age of sixty, sounds are passed for diagnostic purposes. A latent focus is disturbed and a septic process is inaugurated which rapidly invades the blood causing fatal gonorrhœal valvular endocarditis.

A case attended by the writer:— A man claims to have been cured of gonorrhœa eleven years prior to wife's confinement, at which time the child becomes affected with gonorrhœal ophthalmia and the mother with gonorrhœal endometritis and peritonitis. In cases such as this there is the probability of error, on account of the lack of truthfulness on the part of the patient; but their philosophy is not at all obscure. The muscular activity of parturition opens a nidus of bacteria, local infection occurs which is speedily distributed.

Another case of the writer's:— A man supposes himself cured of urethritis, but is injured by falling, which causes return of his dysuria, with the addition of hematuria and true gonorrhœal cystitis, which becomes chronic and intractable. An attack of urethral calculus furnishes opportunity for ascending infection with the development of pyelitis with its characteristic signs which subsides after a time leaving the pre-existing conditions.

The state of latency is not limited entirely to the gonococcus, but our most frequent and important clinical illustrations are furnished by it. Baumgarten and Behring have shown that tubercle bacilli may remain inactive for a long time. Malaria furnishes another example of latency, and recently Panichi (Cent. f. Bakt. 1905, xxxvi, 25) has shown that bacteria, particularly pneumococci, may survive in a highly unfavorable environment without causing pathological states until some special condition favorable to their metabolism occurs.

Many cases of sub-acute gonorrhoea present no gross appearances whatever. In the male a sub-acute state manifests itself occasionally, and as any urethral discharge is an evidence of disease the patient, if properly instructed previously, is likely to resume treatment. In the female, however, the infection may be uterine or vaginal and the discharge very slight; and as vaginal discharge is very common in women, and there may be no symptoms save those which are frequently due to other causes, the condition is not recognized. And then, again, we occasionally find cases in which a supposedly cured gonorrhoea suddenly extends without any apparent cause, — without history of accident, traumatism or bodily exertion. In women, years after the inception of the gonococcus, without any warning or apparent cause for acute exacerbation, a pyosalpinx or perimetritis develops which runs an acute course and merges into chronicity.

The symbiosis of the gonococcus, then, may at any time become a state of paracitism and cause the complications with which this paper deals.

The question naturally arises as to the probability of complications in untreated cases of gonorrhoeal urethritis, a question which at present cannot be answered. In an experimental case See (*op. cit.*) found that complications arose in spite of every care, and Le Fort found from his records that epididymitis was more frequent in the untreated. We know, too, that a very considerable percentage of cases in women first seek professional advice for the sequels of the disease, and we must conclude that although certain complications are furthered by the mechanical features just discussed, they cannot be held wholly responsible.

IV.

SEQUELAE COMMON TO BOTH SEXES.

Ocular Complications of Gonorrhoea.

Gonorrhoea affects the eye both by the living cocci and their toxin apart from the parent organism, and infection is by direct external implantation and by the blood and lymphatic streams. The former causes conjunctivitis and ophthalmia; and the latter scleritis, iritis, retinitis and suppurative keratitis.

Ophthalmia is one of the most common complications of genital gonorrhoea, and is, of course, most frequent among infants. In 1,498 cases of ophthalmia collected by Stephenson (*Am. J. Obst.* xliii, 554), 60.17% were gonorrhoeal. In 1,178 blind patients, Dumas found that 1,070 became so from curable diseases, and of these 69% were from ophthalmia neonatorum. Out of 58,000 blind persons, Hirst found that 15,000 were made so by gonorrhoeal ophthalmia. Neisser claims that there are now 30,000 persons in Germany in whom blindness was caused by this disease; and, at institutions for the blind, gonorrhoea is considered a cause of 46% of all cases in Paris, 20% in Switzerland, and in 25% to 50% in American institutions. Modern methods of treatment must again be invoked; for in 200 cases of gonorrhoeal ophthalmia treated by Hirschberg but six terminated in complete blindness. In

378 cases treated by Hein, 317 were completely cured and 61 had impaired vision; in 161 cases Épéron had but eleven bad results, and of these seven presented lesions when first treated. King considers that 25% of all blindness is due to gonorrhœa. Credé found 10.8% of the babies in the Leipzig Lying-in Hospital affected with it; but, within a few years, under his improved method of prophylaxis and treatment, this was reduced to less than .1%. It has been supposed that the infant acquires the infection during its passage through the parturient canal, which is true in some cases, but in a great many the infection is received after birth; for our knowledge of the biology of the gonococcus teaches that its period of incubation is from a few hours to six to ten days. In 476 cases studied by Andrews (N. Y. Med. J. 1855,) 57 began before the fifth day after birth, 134 before the ninth day, 94 before the fifteenth day, and 194 after this time. The writer has seen a number of cases develop after the tenth day. This knowledge shows how necessary it is to practice the strictest precautions in suspected cases. The late development of ophthalmia is explained by the well-known exacerbation of latent or sub-acute infection by the mechanical forces of parturition already described.

In proof of the supposition that ophthalmia might be caused by the toxin as well as by the living organism, deChristmas (Ann. de l'Inst. Past. xiv, 331) prepared a sterile toxin which he found distributed both in the culture medium and in the body of the bacterium. He found that it was albuminoid in character, soluble in glycerine, precipitated by absolute alcohol and destroyed by high temperatures. Ten drops of

his filtrate when injected into the eye caused intense congestion of the upper half of the eyeball, most intense at the point of injection and fading with radial distance. With decreasing doses the effect diminished, and with three drops only a slight redness at the point of injection, covering one-fourth of the eye-globe, was observed. If the injection be made into the anterior chamber instead of into the conjunctiva, corneal cloudiness, hypopyon, and even loss of the entire eye from panophthalmitis may result.

For Randolph's method of preparing gonotoxin, see Bacteriological Considerations. In his experiments on the eye the conjunctival sacs of white and gray rabbits were kept full of filtrate for periods of from fifteen minutes to eight hours, but in no case save one was there any reaction whatever. In this case a five-hour instillation caused ocular and palpebral congestion followed by conjunctivitis with slight muco-purulent discharge. The repetition of the experiment into the other eye of the same animal was entirely negative. When injected into the conjunctiva ten drops of his filtrate caused intense reaction. Sections show a thick exudate resting on the epithelium, distended blood vessels, and the sub-epithelial connective tissue filled with closely packed leucocytes. When injected into the anterior chamber five drops caused pericorneal congestion, iritis with cloudiness of the aqueous, — all disappearing within seven days.

Gonorrhœal ophthalmia usually appears within twenty-four hours of inoculation with redness and swelling of the lids, burning and smarting pains, systemic malaise and slight elevation of temperature. Great swelling of the eyelids, chemosis of the conjunc-

tiva, hemorrhages from the rupture of small vessels and an infiltration ring around the cornea may result in extreme cases. If neglected, perforation with hernia of the iris may take place, thus admitting infection to the interior of the eye and causing panophthalmitis; or the process may be arrested at this stage and result in staphyloma of the cornea.

Histologically the entire conjunctiva is infiltrated with leucocytes, the inflammation being most intense in the superficial layers. There is more or less complete desquamation of the epithelium and its replacement by a dense layer of pus corpuscles containing gonococci. In most cases the cocci are limited to the outermost layers of the sub-epithelial connective tissue in rows or masses between the fibre bundles; occasionally they may penetrate deeply into the conjunctival tissue. The teaching that the formation of a croupous membrane is a natural protective measure assisting the healing process does not apply in this case, and experience teaches that cure is accomplished only by the prompt use of bactericides,—indeed, it is often necessary to employ in the conjunctival sac solutions which would not be tolerated in the urethra.

Rarely a case is seen in which a child is born with gonorrhœal ophthalmia,—in such cases there is usually a history of delayed labor with early rupture of the membranes, thus allowing vaginal infection to invade the amnionic sac before birth.

Gonorrhœal ophthalmia, both in adults and infants, is often a primary affection and may be the source from which complications proceed. It is a frequent cause of gonorrhœal arthritis of the young and even of the newly born.

In order to prove if it were possible for conjunctivitis to be caused by normal lochia, Zweifel inoculated the conjunctiva but with negative results.

Iritis and Iridochoroiditis.

These may or may not be associated with gonorrheal conjunctivitis and they develop much more rapidly than ordinary rheumatic iritis. The inflammation is serous rather than plastic and presents in brief the following features: sudden onset, very rapid development, severe ocular pain, rapid and complete loss of vision due to serous infiltration of the iris and choroid with cloudiness of the aqueous and vitreous precluding the possibility of ophthalmoscopic view of the fundus. Fibrinous exudate is never observed and synechiae are rare, but when they do occur are feeble. Five cases reported by Bull (Med. Rec. Dec. 20, 1902,) were all secondary to gonorrheal arthritis and one was followed by gonorrheal endocarditis.

Pathology: in gonorrheal iritis there is small celled infiltration of the iris which is general or may be in scattered foci or along the vessel sheaths. There may be small hemorrhages giving the appearance of punctate echymoses or the inflammation may go on to suppuration with the appearance of a fibrinous exudate and pus in the anterior chamber.

Gonorrheal Panophthalmitis is caused in two ways, — by the perforation of corneal ulcers from the destructive lesions of conjunctivitis allowing the evacuation of the eye fluids thereby causing collapse of the globe, — or by the rapid invasion of eye tissues by the

gonococcus which causes at first intense congestion and swelling, but afterwards contraction and shrivelling with progressive destructive suppuration.

Dacryocystitis of gonorrhœal origin does not differ materially from that caused by other pyogenic organisms.

Otitis Media and Mastoiditis.

Very rarely, indeed, gonorrhœal infection shows itself in the ear as is illustrated in the unusual case observed by Trow (Med. Rec. May 2, 1903, 693) occurring in a man of fifty-two years. Although the patient denied venereal disease, purulent otitis media was followed by mastoiditis, the pus from which showed typical gonococci. Operation was followed by prompt and uneventful recovery.

Stomatitis and Gingivitis.

Gonorrhœal stomatitis is very rarely observed in adults, but is quite frequently seen in the new born, the source of infection being usually the maternal genital tract. The disease starts with small punctate cream-colored patches on the buccal mucous membrane which soon enlarge and coalesce and form membranous areas which are even in outline and slightly raised above the surface. The condition resembles oral thrush or diphtheria, there is inflammation with infiltration of the tissues of the tongue, the palatal and buccal mucous membranes soon become covered with a croupous deposit which consists of exfoliated epithelium and pus cells. Smears from these show the gonococcus if taken early in the course of the disorder,

but later may be negative on account of the tendency of the coccus to be overgrown by other bacteria, of which there is a great variety in the mouth. In all cases this process is distinctly local and does not spread unless the system be greatly reduced.

A case reported by Vines (Br. Med. J. Feb. 21, 1903, 425,) shows not only that gonorrhœa may become engrafted in the mouth as may syphilis, but also that it may cause pyorrhœa alveolaris and gingivitis of the most severe form. A man who had been suffering with gonorrhœal urethritis for a month used an infected toothpick; the gums shortly became inflamed, red, swollen, painful, bleeding and spongy, all the teeth became loose, every socket was bathed in pus, and the condition resisted all forms of treatment until silver preparations were used. A temperature of 101° F. showed a low grade of toxemia from absorption.

Gonorrhœal Arthritis.

This disease is quite distinct from ordinary rheumatism and is caused by the local deposition of gonococci in or about an articulation. It may occur at any age, even in the new born, and occurs most frequently during gonorrhœal urethritis. Fournier, Besnier and Grisolle observed the ratio to be one case in 64, 50 and 35 cases of urethritis which are probably minimum estimates. Men are more frequently affected than women, possibly because their more active physical life offers more opportunities for traumatism to the articulations. In 52 cases observed by Schuller, 34 were in males and 18 in females.

The *symptoms* are quite distinctive. The onset,

though often sudden is not accompanied by the febrile reaction so characteristic of acute articular rheumatism and often the disease is quite febrile throughout its course, the elevation being two degrees or less. Hyperpyrexia indicates mixed infection or the involvement of other organs. Occasionally the pain may be severe, but usually there is but little pain and no intense suffering with motion and manipulation so characteristic of acute articular rheumatism. Swelling is an early symptom due to effusion of fluid into the joint cavity, bursae or tendon sheaths, or the peri-articular tissues. Suppuration is rare and usually due to a mixed infection, but if such cases are incised early the gonococcus may be found in the tissues or effusion. In all these cases there is a marked tendency to fibrous ankylosis and they are extremely chronic, lasting for months or even years.

Joints affected.—The knee is involved more frequently than any other joint. In a series of 119 cases compiled by Garrod, the knee was infected in 83 cases, the ankle in 32, fingers and toes in 23, the hip in 16, the wrist in 14, the shoulder in 12, the elbow in 11, the temporo-maxillary in 6, the tarsus and metatarsus in 5, the sacro-iliac in 4, the sterno-clavicular in 3, the chondro-costal in 2 and the tibio-fibular in 1.

In 52 cases studied by Markheim (Deut. Arch. f. klin. Med. lxxii, 186,) one joint was involved in 13 cases, two in 12, three in 11, four in 7. Endocarditis was observed four times, iritis three times, sciatica once. Complete ankylosis of joints was observed in five cases, limitation of motion in 7 and the gonococcus was demonstrated in the blood in but two.

On account of the persistency of the gonococcus and its tendency to become latent, relapses upon over exercise or injury are very common.

Gonorrheal Periostitis closely resembles gonorrheal arthritis and may be acute and remain as a simple inflammation of the periosteum, or it may extend into the bone and become a true osteitis. (Phillipet, Gaz. hebdomadaire de Med. et Chir. 1901, No. 79.) The condition begins with pain over a distinctly circumscribed area of bone with mounding and puffiness of the overlying tissues. The skin may be red and shiny. It is usually of very rapid development, comes on three weeks after the initial discharge and lasts for two or more weeks. The symptoms then either disappear gradually and cause no more trouble or else persist with the development of plastic hypertrophic periostitis and more or less deformity which may endure for years. This, too, is prone to relapse and recur with fresh gonorrheal infection. A frequent location of gonorrheal periostitis is at the insertion of the tendo Achilles, where the pain may be so great as to render the patient an invalid, the slightest weight borne on the foot causing intense pain.

Fournier and Amaral have observed a progressive pseudo-nodulated deforming polyarthritis after gonorrhea which is characterized by periarticular swellings of the extremities of the phalanges, metacarpal bones or great toe. Smooth, hard exostoses form on the extensor and lateral sides, but never on the flexor. There is pain on the first appearance of the tumefactions but none later, nor is there any redness of the overlying tissues. If the inflammation

extends over the joint between the first and second phalanges, we have the fusiform or radish-shaped joint which is pathognomonic of the disease, but which must be differentiated from tuberculosis and sarcoma. Haygarth's dactylitis resembles this very closely, but invariably affects all the fingers of both hands.

Chronic osteo-periostitis of the long bones also may occur as a complication or sequel of gonorrhoea. The most common example of this is the hypertrophy of the diaphysis of the femur which occasionally follows gonorrhoeal rheumatism with the formation of an indolent swelling accompanied by an extreme degree of atrophy of the muscles of the thigh. This affection is extremely chronic often persisting for months or even years in spite of the most sincere treatment. It is differentiated from syphilitic affections by the extreme painfulness and the amenability to specific treatment of the latter.

It seems probable that gonorrhoeal infection reaches these various joints by the blood stream and that their lodgment is favored by the looped and terminal capillaries which lie in non-yielding fibrous tissue which is constantly in motion and frequently exposed to traumatism. Cases are on record in which tendon sheaths near joints were involved, but the most careful examination failed to show any connection between the two. Wounds, gonorrhoeal ophthalmia and other extra-genital foci may be the cause of arthritis and occasionally, as observed by Kimball (*Med. Rec.* Nov. 14, 1903, 761,) the source of infection is unknown. Among 600 admissions to the Babies' Hospital of New York, 10 cases of gonorrhoeal arthritis occurred; eight of these were under three months old, and of these all but one were

males. In but one was there conjunctivitis and that developed after the joint symptoms. In none of these cases was there urethritis, vaginitis or any other finding which would indicate the point of entry of the organism.

The course of ordinary cases of gonorrheal arthritis is well known, but the following cases present points of unusual interest.

Gonorrheal arthritis and perichondritis may go on to the destruction of tissue and deprive bones of their necessary support, as illustrated by a case of Widal (Soc. med. des Hop. de Paris, 26 Jul. 1895,) in which a gonorrheal hydrarthrosis caused spontaneous luxation of the head of the radius.

Herman (Med. Rec. May 21, 1904, 815,) reports a case of multiple periartthritis in a child in which the infection was received through a wound of the foot.

Bordone-Uffreduzzi (Deut. med. Woch. xx, 484,) obtained the organism in pure culture from an infected ankle joint, and established the certainty of its etiology by the successful inoculation of the urethra of a healthy man.

Two cases of gonorrheal affection of the sternal end of the clavicle are of interest. (Jn. Am. Med. Ass. Aug. 27, 1904, 608.) One in a man of twenty which occurred three weeks after the beginning of an untreated urethritis; the other a man of twenty-one, two weeks after appearance of the urethral discharge, there appeared a globular swelling the size of a hen's egg which was at first supposed to be a rapidly growing osteo-sarcoma.

Illustrative of gonorrheal arthritis of the new born Haushalter (Arch. clin. de Bordeaux, iv, 495,) observed

a case in a child of twenty-eight days. Three days after birth double conjunctivitis appeared in very virulent form causing loss of both eyes. Griffon (Presse Med. 19 Fev. 1896, 88,) reports a similar case of double purulent ophthalmia with perforation of one eye and suppuration of the right hip and wrist joints. Death on the thirteenth day of the arthritis from general pyemia. Autopsy showed gonococci in abscess cavities of both affected joints. Blood cultures taken a week before death showed staphylococcus albus and a bacillus closely resembling Klebs Loeffler. This interesting case illustrates the co-existence of other bacteria which were introduced with and by the gonorrheal infection. Still another case by Paulsen. (Jhns. Hop. Hospt. Bull. cxliv, 98.) A child develops gonorrheal ophthalmia on the third day which runs an uneventful course and yields promptly to treatment. On the eleventh day the left knee becomes swollen and aspiration of the effusion shows the gonococcus in pure culture.

Teno-Synovitis has been thoroughly discussed by Bloodgood and Flexner (Jhns. Hopk. Hospt. Bull. lxi, 58,) and by Jacobe and Goldmann (Beit. z. klin. Chir. xii, 672).

A monograph by Vernon-Jones (H. K. Lewis Co., London) offers additional information on gonorrheal affections of the joints.

Myositis.

Not only is myalgia a frequent accompaniment of gonorrheal arthritis, but the coccus actually invades muscular tissue and causes all grades of inflammation

from infiltration to actual suppurative destruction. The general features of this complication are best illustrated by abstracts of case histories.

In a case worked out by Ware (*Am. J. Med. Sci.* cxxii, 11,) a man in the fourth week of gonorrhœal urethritis is taken with chills, temperature and pains in the knee joint. Several weeks later there is pain and swelling in the left shoulder joint. Incision in the posterior axillary fold shows turbid serum, the cultures of which remained sterile, but no pus. A portion of the muscle, however, was excised and sections showed interstitial inflammation with liberal scattering of gonococci in pairs about the nuclei of the leucocytes and in the interstices of the muscle. Portions of the muscle fibres showed cloudy swelling and there was multiplication of the muscle nuclei with shrinking of the perimysium. Between the fibres there was marked proliferation of connective tissue. In this case we have another interesting example of deep invasion by the gonococcus and of the state of fibrosis which this organism is supposed to occasion.

Rona (*Arch. f. Derm. u. Syph.* 1898, 250,) reports two cases in which inflammation did not go on to suppuration. The first in a man of twenty-seven in whom pain in the thigh was followed by induration which was very tender on palpation, lasted many weeks and was at no time accompanied by redness or swelling of the overlying skin. The other case, a man of twenty-seven with fourth attack of gonorrhœa. In the second week of the attack pain begins in the middle of the left thigh and is followed by infiltration of the fascia lata the size of a saucer. Rest in bed

was necessary for two weeks, but at no time was there any elevation of temperature.

Eichorst (Deut. med. Woch. 1899, 685,) records a case of a man of fifty-six, who, in the fourth week of his first attack of urethritis, is taken with severe pain in the outer aspect of the thigh followed by the development of a painful induration 4 by 8 cm. Temperature from 35° to 38° C. Two weeks later gonorrhœal arthritis appeared in the wrists.

Treves has observed a case of gonorrhœal myositis in which the muscle afterwards became sclerotic, the condition resembling that which causes ankylosis of the joints.

Harris and Haskell (Med. News. Feb. 21, 1903, 381,) have observed a case in which tumefactions appeared in the calf of the leg and in the sacro-lumbar region. Leucocytosis of 16,000. Incision releases 760 cc. of bloody pus from the abscess in the leg and drains a large intra-muscular abscess in the sacral region. The gonococcus is demonstrated in smears and cultures from both.

Causing Abscesses and Phlegmonous Inflammations.

These may be caused at almost any portion of the external surface of the body, and are due to direct inoculations or to metastasis. Ophthalmia and urethritis are the most common antecedent lesions. Gonorrhœal abscesses are usually superficial but may be deep seated, as is shown in the discussion of glandular diseases and myositis. The pus from them may or may not show the gonococcus for the reasons already discussed. The experiments of Wassermann,

who injected gonotoxin into his own arm have already been referred to.

Bujivid (*Cent. f. Bakt. u. Parasit.* 1895, 435,) reports an interesting case of a man of thirty-two years with posterior urethritis. Two days after catheterization he had severe chills for six days which were followed by the development of multiple abscesses in the left elbow joint, the right popliteal fossa, the inner side of the left calf and over the right external malleolus.

The writer has operated on several periurethral abscesses in which smears showed the gonococcus, which did not communicate with the urethra and which healed quickly when incised from without. Such cases prove conclusively that the coccus does penetrate below the mucosa, for in none of these cases had there been any instrumentation or other traumatism which might assist their progress.

Gonorrhœa is a common cause of abscesses of the perineum and ischio-rectal fossa, due in some instances to false passages from instrumentation and in others to gonorrhœal phlebitis of the prostatic plexus. Gonorrhœal proctitis may be the cause. Periurethral abscesses are so common as to need no special discussion.

The interior of gonorrhœal abscesses often presents an appearance regarded by many as pathognomonic of the gonococcus. This is a characteristic picture with dark red granulations which bleed easily and tend towards a fungoid appearance. Abscesses of gonorrhœal origin in the deeper portions of the perineum and ischio-rectal fossa differ from cutaneous suppurations in being very much slower in healing, the surrounding surfaces are infiltrated and spongy

but as a rule not of edematous hardness, and the systemic depression and anemia is often intense.

When pudendal abscesses complicate syphilis they may often be termed syphilitic buboes of gonorrheal origin. The system, already depressed by the syphilitic virus allows invasion by other bacteria, and an intercurrent gonorrheal urethritis is very frequently followed by enlargement and suppuration of the inguinal glands showing either the gonococcus or a mixed infection. If of slow development they may be sterile, and if operation be aseptic, primary union may be realized and should be attempted. Abscess formation will be frequently referred to throughout this work.

Adenitis.

It was formerly thought that the gonococcus was incapable of causing adenitis, but recent examinations have shown that while this organism does not show the affinity for glandular tissue exhibited by other bacteria, yet it is, of itself, quite capable of causing adenitis of all grades and of nearly all parts. The group of glands just above Poupart's ligament and outside the fascia lata are those most commonly affected, and their enlargement may be looked for after the first week of the urethritis.

Cervical adenitis has been caused by the gonococcus as has been shown by Pettit and Pichevin (Mal. Cut. et Syph. 1896, 419,) the infection being either from the urethra by the blood stream, or else more directly from a wound.

The only special study of the lymphatics in acute gonorrheal urethritis made thus far is that of Nobl

(Klin. thera. Woch. xxix.), who found the cocci in the substance of the glands in five out of nine cases studied.

Mastitis. — The writer offers the report of a case of puerperal mastitis occurring in a woman who acquired gonorrhœa shortly before pregnancy, in which multiple abscesses requiring operation formed in the left breast. There were also small pustules in the integument and near the umbilicus, also showing gonococci. Freeth (Lancet, Jn. 6, 1904,) reports a case of mastitis in the male, secondary to gonorrhœal urethritis, the pus showing the cocci.

We see, then, that the gonococcus is occasionally the cause of cutaneous, cellular and glandular abscesses, and that it vies with the streptococcus and staphylococci in this respect. The philosophy of this difference is apparent from the cultural characteristics of the gonococcus.

Cystitis.

Cystitis is a very common complication of either acute or chronic gonorrhœal urethritis. It occurs more frequently in men than in women, on account of the frequent involvement of the prostatic portion of the urethra, the tendency to stricture, and the preponderance of the various mechanical forces which we have already discussed as furthering the extension of bacterial inflammations. The various factors which cause vesical congestion, inseparable from gonorrhœal urethritis, need not be discussed; but this congestion is occasionally so great that rupture of venous capillaries may take place, thus affording opportunity for the

lodgement of the gonococcus and the development of a focal suppuration. Calculi or tumors of the bladder act as mechanical irritants and cause a chronic cystitis which may become gonorrhoeal whenever there is the added infection; papilloma, in particular, acts as a host for bacterial colonies, and the cystitis which such a combination fosters is intractable and long enduring.

The pathology and symptoms of gonorrhoeal cystitis are not distinct from that caused by other organisms. The mucosa is swollen and congested, bearing red spots of ecchymosis which may break down and form bleeding ulcerations with granulating surfaces. The ureteral openings may be obstructed. In a case of Wertheim (Deut. med. Woch. xvii, 1895, 118,) of a girl of nine years with gonorrhoeal vulvo-vaginitis, arthritis and acute cystitis, the excision of a small millet seed tubercle on the posterior portion of the mucous membrane of the bladder showed a large number of capillary veins in the submucosa to be filled with large numbers of gonococci, while the arterial capillaries contained none. Cultures from the urine and the tissue showed the gonococcus in pure culture.

In an interesting case of cystitis, prostatitis, purulent arthritis, splenic infarction and prostatic folliculitis, observed by Finger, sections of the bladder showed similar engorgement of the capillaries with leucocytes, infiltration of the perivascular tissues by the gonococci, and undermining of the epithelium.

In addition to these cases, the researches of Young (*op. cit.*) place our knowledge of gonorrhoeal cystitis upon a basis of scientific certainty. Owing to the impossibility of obtaining urine that was uncontaminated by the secretions of the urethra he aspirated

the bladder through the abdominal wall without harm resulting. One of his cases is of particular significance. Patient with chronic cystitis of five years duration following gonorrhea, double pyonephrosis, atony of bladder, retention of urine. Upon aspiration of the bladder, gonococci were found in pure culture and in great numbers. At first gonococci alone were found, then bacilli and streptococci began to appear in increasing numbers. On the seventeenth day there were fewer gonococci than other bacteria, and in ten weeks they were greatly outnumbered by bacilli and streptococci, both of which were intracellular and in great numbers. This secondary infection occurred in spite of intra-vesical irrigations of bichlorid and the most rigid aseptic technique.

Ascending Gonorrheal Infection.

Having seen how the bladder may become infected from the urethra and suggested the commonness of the complication, the important question of ascending infection naturally presents itself. It has already been noted that catheterization of the ureters might carry particles to the renal pelvis, and the writer has briefly reported a case in which the injury inflicted by a ureteral calculus afforded opportunity for secondary gonorrheal infection. The question of reflux from the bladder into the ureters has received much deserved attention. One recalls the intense pain in the lumbar and kidney regions which accompanies bladder retention and disappears promptly when the distension is relieved. Lewin & Goldsmith (Virch. Arch. cxxxiv,

S. 33,) showed that reflux took place in anesthetized rabbits. Jacobelli (*La Rif. Med.* 1901, xvii, 27,) has shown that fluids suddenly injected into the bladder may pass up into the ureters, and one might suppose that the same thing would occur in case of blows over the bladder. Young and Stoeckel were unable to verify these findings, but Marcus (*Wien. klin. Woch.* 1903, xvi, 725,) observed both reflux and reversed ureteral peristalsis in animals. Sampson (*Jhns. Hopk. Hospt. Bull.* Dec. 1904, 341,) has made a notable series of experiments on dogs, making nineteen transplantations of the ureter, and observed no reflux in any degree of bladder distention nor reversed peristalsis. There is, however, considerable clinical evidence that reflux does take place in the human species. Pozzi (*Cent. f. Gyn.* xvii, 98,) accidentally severed a ureter while removing a large intraligamentary ovarian cyst, and observed that urine came from both ends of the ureter. Warschauer (*Berl. klin. Woch.* xxxviii, 399), in a case of disease of the ureteral orifices, filled the bladder with colored fluid and later recovered this fluid from the pelvis of the kidney with the ureteral catheter. Sampson relates an interesting case in which a patient could actually feel fluid pass up into the ureters when the bladder was filled and a previously existing vesicovaginal fistula was closed by the operator's finger. Stricture of the ureter with resulting retention of urine above the stricture is undoubtedly a cause of ureteral infection, the retained urine remaining in situ long enough for organisms to invade the tissues, a thing which could not have taken place had the adventitious bacteria been promptly washed down by the urine current.

Of all the cases of gonorrheal pyonephrosis reported in literature and reviewed by the writer, none fulfil the requirements of exact bacteriology, in none has the gonococcus been found in the kidney substance. It can safely be predicted, that this stipulation will soon be satisfied: the following cases illustrate the pathology of this form of ascending renal infection:—

Cumston (Univ. Med. Mag. Penn. Phil. June, 1899, 504,) Cystitis, following two weeks after the onset of acute gonorrheal urethritis, is complicated by chills, elevation of temperature; blood, bladder cells, pus, casts, albumin and cells from the renal pelvis are found in the urine. A swelling in the region of the left kidney then develops, and operation on this, five weeks after the onset of the urethritis, releases 1.25 litres of pus. The kidney substance was not destroyed, and the pus came from the distended pelvis. Unfortunately no bacteriological examination of the pus was made.

Berg reports a case of fatal endocarditis (Med. Rec. lv, 602,) in which a renal complication developed after the arthritis and heart condition, probably from the deposition of septic particles from the blood stream. The absence of cystitis proved that there could be no ascending infection. Pain and tenderness over the left kidney were explained by the finding post-mortem of hemorrhagic spots in the pelvis of the left kidney which contained turbid serum in which were found diplococci decolorizing by Gram's. Young also reports a case with practically the same history.

Our knowledge of the bacteriology of cystitis in women would lead us to believe that gonorrhoea is not a frequent cause in this sex. In sixty cases studied by

Brown bacteriologically (Jhns. Hopk. Hospt. Rpts. x, 48,) the *B. coli* com. was found thirty-one times, *Staph. albus* seven times, *T. B.* six times, the *Staph. aureus* five times and the gonococcus not at all. In 80 cases of infection of the entire urinary tract there were no findings of the gonococcus, but the *B. coli* was found thirty-eight times and various staphylococci eighteen times. In 35 cases of cystitis in women, Melchoir found the gonococcus but once; and in 120 cases collected from literature, Rostoski found it but three times.

It has been thought that ascending gonococcus infection might be a factor in the causation of renal diabetes. Luethje (Munch. med. Woch. Sept. 17, 1901,) reports an interesting case of this disease following gonorrhoeal pyonephrosis.

Rectal Gonorrhoea.

Rectal gonorrhoea may result from auto-infection or from the implantation of the cocci in any manner. It differs from the other complications of gonorrhoeal urethritis in that it is not metastatic, but is nearly always from the direct deposition of material in the rectum or upon the anal margin. The cases reported by Neisser, Bumm, See, Lang, Staub, Frisch and others do not begin to indicate the frequency of the affection. Rectal gonorrhoea has been observed epidemic among infants in an institution in which the thermometer used for taking rectal temperatures was not properly cleansed or protected, one case serving to infect an entire ward. Weil observed 30 cases contracted in this way. The affection may be primary and the individual escape genito-urinary infection.

The pathology and symptoms are very variable, - the clinical pictures varying from a condition of advanced inflammation and sepsis, with profuse discharge, rectal and anal ulcerations, acuminate condylomata and ischioanal abscess, to slight rectal folliculitis with but little secretion. The course of the disease also varies within wide limits, some cases resolving within a week, others being chronic and resistant to treatment. Untreated cases rarely undergo spontaneous cure. The following are the chief pathological features: infiltration of the mucous membrane, croupous exudate of pus and desquamated epithelium, edema and infiltration of the integument causing temporary stenosis of the anus, acuminate enlargement of the rectal follicles, necrosis of their apices leaving small ulcerations which may coalesce, forming large ulcerative areas. The tissue involved is friable, granulating and spongy, and bleeds freely on the slightest abrasion.

In a case reported by Frisch (Ueber gonorrhoea rectalis, *Allgem. med. Cent.* 1902, No. x,) the gonococcus was found in the rectal discharges, ulcerations, in the glands and periglandular tissues, and in the perirectal tissues as far as the same were explored by incisions.

The ease with which therapeutic agents may be applied to the rectum should make this disease one of short duration and without sequelae.

Two extremely interesting cases of ulcerative perforation of the rectum from gonorrhoeal salpingitis have been reported by Otradovec (*Am. J. Med. Sci.* cxxiv, 665, April, 1905). The first, a woman of eighteen years, presenting the physical signs of parametritis with abdominal swelling and obstipation, is

operated on for intestinal obstruction. At operation the great omentum is found fused into a large mass from which two stout bands dip down into the pelvis incarcerating several loops of intestine. Death a few hours after operation. Post-mortem: the peritoneum is found reddened, there is great meteorism of the intestinal loops, and behind the uterus a pus cavity 3 cm. by 6 cm. is found which perforates the rectum by a pin hole aperture which is surrounded by a raised irregular ulceration $1\frac{1}{2}$ cm. long. The tubes contain pus and both tubes are infiltrated with pus cells containing gonococci.

In the other case a woman of forty-six has had abdominal pain, vomiting and constipation for five weeks, and is now disabled with dyspnea and swelling of the body and limbs. Physical examination shows tumor of the uterus, bronchitis and uncompensated aortic valvular insufficiency. Death occurs from pulmonary edema after a course of symptoms quite like those of any uncompensated heart lesion. Post-mortem the following lesions were found: chronic deforming aortic endocarditis, multiple cardiac myomalacia, fatty degeneration of myocardium, vegetations in left ventricle, bilateral suppurative gonorrhoeal salpingitis, circumscribed ulceration of peritoneum with perforation of rectum, dilatation of lower extremity of left ureter, stenosis of vesical entrance of both ureters, left pyelitis, calculi of left kidney.

Gonorrhoeal Invasion of the Skin.

Gonococci invade the skin by direct implantation from the contagion of overflowing discharge, or in-

directly through the cutaneous lymphatics or vessels. The former is of course the more frequent occurrence.

The condition produced by gonorrhoeal discharge is usually of an eczematous or erythematous character, the first symptoms being redness and swelling which soon proceed to actual infiltration and edema. If no treatment be instituted, and if the skin is not protected from further irritation, there may be exfoliation of the stratum corneum and desquamation of the strata lucidum and Malpighii, leaving ulcerations which are extremely painful if in proximity to cutaneous nerves. These ulcerations and the dermatitis causing them are usually acute and quite amenable to treatment, but in depressed systemic states may become chronic and assume a pruritic type, the vulvitis pruriginosa of Sanger. Rarely, gonorrhoeal ulcers may become serpiginous and phagadenic causing very considerable loss of tissue. Thalman (*Arch. f. Derm. Syph.* lxxi, i, 1904, 75,) observed two cases of this kind, in both of which typical gonococci in pure culture were found in sections of the tissues. In the first case an ulceration of the posterior vaginal wall penetrated the perivaginal tissue and caused a retro-vaginal fistula in spite of careful and persistent antiseptic measures. In the second case the ulceration of a broken-down buboe spread with great rapidity until it involved the entire inguinal and pubic regions. Even the actual cautery failed to inhibit the extension of the ulcerative process, but when the true nature of the case was discovered by the section, the employment of silver preparations was followed by immediate improvement.

Another case observed and reported by Salomon and Blaschko (*Munch. med. Woch. Mch.* 3, 1903,) is

illustrative also of the phagadenic form of gonorrhœal ulceration of the skin and of the helpful effect of silver compounds after resisting other forms of treatment.

Maculae Gonorrhœicae are peculiar indurated red macules which mark the entrance to the ducts of the glands of Bartholin and are due to gonorrhœal inflammation of these glands. Rarely, they appear in inflammation from other bacteria.

Pemphigus Bullosus of the new-born has been observed by Krakow (Gaz. Lekarska, 1894, 632,) in a case of gonorrhœal ophthalmia, the mother having gonorrhœal puerperal sepsis and arthritis.

Pruritus. — Gonorrhœal arthritis may be accompanied by intense pruritus over the affected joints, as has been observed by Domenici (Gaz. Ospedale, Mch. 1, 1903). In this case the pruritus was not helped by any method of treatment, but ceased suddenly upon improvement in the arthritis.

Urticaria over the whole body has been observed by Orlipsky (Munch. med. Woch. Oct. 7, 1902,) who describes it as vanishing with the cessation of the gonorrhœa and not differing in any from urticaria from other causes.

Diffuse Erythemas and *Exanthems* are occasionally observed during gonorrhœa of children. Ordinarily there is a bluish or red rash with local heat of the skin which is evanescent, but which in severe cases may go on to furunculosis or suppuration. These may

be characterized also by small papules which soon change into vesicles containing either clear or turbid serum or pus, in which the gonococcus is usually found.

An interesting condition of the nails caused by gonorrhoea has been observed by Vidal, Jeanshew, Stanislawski, Krotoszyner and others. A line of demarcation appears between the matrix and body of the nail, the outer half formed by this margin turns grayish-white, the border becomes frayed and ragged, there is progressive marginal lifting of the nail until it falls off. This process is sometimes painful but is usually painless. Swelling and redness of the finger tip may or may not be present, and regeneration of the nail is exceedingly slow.

Herpes Gestationes.—Touton (iv Congres de la Soc. Allemande de Dermat. Breslau, 1904,) has found an organism conforming with the morphological and staining qualities of the gonococcus in the lesions of a case of herpes.

Another rare cutaneous manifestation of gonorrhoea has been observed by Baermann (Arch. d. Darm. u. Syph. lxi, Heft. 3,) in two cases of gonorrhoeal pyemia. In both cases the lesions were polymorphous and were either disseminated over the entire body or else were limited to the hands and feet. In the former case the appearance of vesicles is followed by the formation of crusts and scales which are laminated, cone-shaped, and firmly adherent to a moist, red, papillomatous base. In lesions of the hands and feet there is thickening of the stratum corneum of the palms and soles and upon these areas there are discrete or con-

fluent conical protuberances which are either smooth or fissured. The nails become brittle and may fall off, leaving the oozing surface of the underlying epidermis. These lesions frequently occur in plaques on the lower extremities, particularly on those atrophied by joint disease. Microscopically there is proliferation of the papillary layer, induration of the vessels which are surrounded by an area of leucocytic infiltration, migratory cells are found in the deep layers of the epidermis, and the horny masses show incompletely cornified parakeratotic cells, their nuclei being still visible.

Gonorrhœal Affections of the Nervous System.

Gonorrhœa affects the nervous system by the direct local action of the cocci and by the toxin circulating in the blood stream. The former results in meningitis, myelitis, and perhaps neuritis; the later in neuralgia, neuritis, neurasthenia and mental states.

After inoculating animals with gonotoxin, Moltschanoff found degenerative lesions resembling tabes in the posterior columns of the spinal cord.

Neuralgia is a comparatively common accompaniment of urethritis and arthritis and occurs most frequently in the sciatic nerves. Kalabin (Cent. f. Gyn. 1903, xxvii,) observed two cases of sciatica and intercostal neuralgia in women who became infected shortly after marriage. In both of these cases nerve pain began two weeks after the beginning of the discharge and ceased with improvement in the local condition a month later. This observer, from a thorough study of the subject, is convinced that there is a direct rela-

tion between the two and suggests the possibility of irritation of the brain by the toxin.

Neuritis. — As might be supposed, a nerve traversing a tissue mass infiltrated by coccus-bearing cells would be likely to participate in the inflammatory process and exhibit the usual symptoms of neuritis. Keinbock (Samm. klin. Vort. cccxv.) observed such a case in which there was infiltration of the region of the olecranon, arthritis of the shoulder joint with crepitation, and atrophic changes in the skin and nails.

Panas (La Sem. Med. 1890,) observed a case in which there was inflammation of the cranial nerves with transient deafness, diplopia, and the usual signs of optic neuritis.

Tambourer (Soc. de Neuropath. et d'Alien. de Moscou. 21 Jan. 1894,) observed an instructive case of multiple gonorrhoeal arthritis and gonorrhoeal phlebitis in which lesions of the intervertebral articulations caused pressure on the vertebral nerves. Death resulted from cerebral embolism secondary to the gonorrhoeal thrombo-phlebitis.

Pitres (Accidents cerebraux dans le cours de la Blen. Rev. Neurolog. 1894, 441,) reports two similar cases of cerebral softening following gonorrhoea.

Glynn (Lancet, Sept. 27, 1902,) reports and discusses two cases of paralysis of gonorrhoeal origin, one of ascending paralysis with peripheral neuritis, the other of pseudo-tabes. Both of these recovered. Raymond (Prog. Med. 27 Juil. 1901,) reports cases of ascending paralysis and polyneuritis. Gull (Trans. New Sydenham Soc. 1880,) reports three cases of myelitis of

gonorrhœal origin, and Charcot (Diseases of Nervous System, 1880,) includes gonorrhœa as one of the causes of degenerations of the spinal cord.

Meningitis of gonorrhœal origin has been observed by Panas and was characterized by elevation of temperature, intense headache and eye symptoms ending in optic atrophy. In a case of Jullien (Trans. French Assn. G. U. Surgeons. Oct. 21, 1897,) recovery followed in the case of a young girl in whom gonorrhœal vaginitis was complicated by teno-synovitis, hygroma, myositis, nephritis and meningitis. Skin symptoms consisting of rose-colored lenticular spots appeared during the course of the meningitis. Von Leyden observed a case due indirectly to gonorrhœa. Primary gonorrhœal urethritis was followed by acute gonorrhœal cystitis which became chronic. Paraplegia and death resulted from the urinary infection, and autopsy showed degeneration of the posterior columns of the cord. (Zeit. f. klin. Med. 1892, xxi, 5.)

But of far greater importance than these is a case observed by Furbringer (Deut. Med. Woch. 1896, No. 27,) in which the lumbar puncture of a case of cerebro-spinal meningitis showed fluid containing typical gonococci, as did the exudate on the meninges observed post-mortem. Through the courtesy of a scientific layman the writer is able to give brief facts of two cases of gonorrhœal paralysis. The first, a man of thirty-two has gonorrhœal arthritis and synovitis of both knees and ankles, — no operation. Three years after the initial urethritis, paraplegia develops. In the other case, a man of thirty has gonorrhœal synovitis of one knee which is followed by sensory paralysis

of the affected leg which improves only after a prolonged course of treatment.

Affecting the Mental System.

The numerous mental complications of gonorrhoea may be divided into two classes,—those due to the moral and social circumstances of venereal disease, and those resulting from the anemia, systemic reductions caused by prolonged suppuration, and from the irritation of the toxin on the brain. The probability of nervous and mental disorders and the reasons therefor in cases of gonorrhoea insontium are too apparent to require special discussion. In the latter class, the induced anemia together with gonotoxin may act as a precipitating force upon a mental predisposition, just as bacterial diseases of other kinds, as well as the complicated poisons of auto-intoxication, may be the final forces which overtax the already burdened system.

In twenty-two cases of hebephrenia studied by Venturi, twelve had gonorrhoea, which he considered responsible for the following phenomena,—stupor, hallucinations, somnolence and hypersensitiveness: of objective symptoms,—delirium, attempts at suicide, choreiform movements, maniacal excitement, increased skin reflexes, cataleptic and catatonic states. These symptoms for the most part disappeared with the venereal disorder. The writer has recently observed a case of nocturnal delirium complicating acute gonorrhoeal urethritis which was characterized by slight elevation of temperature, somnolence during the day, but throughout a marked elevation of pulse tension.

Widal and differential white count negative,—improvement in the mental condition with urethral treatment.

Neurasthenia, particularly of the sexual type, and hypochondriasis are also frequently observed. Krotoszyner (Trans. San Fran. Co. Med. Soc. Dec. 11, 1900,) in a large experience of foreign genito-urinary wards found that 60% to 70% of all cases of gonorrhœa presented such symptoms.

Gonorrhœal Affections of the Pleuræ and Lungs.

The occurrence of pleurisy during inflammation of other organs has been often noted. Lapeyre (Essai sur les complications perihepatique et pleurales de l'Appendicite, Rev. de Chir. xxii, 508,) quotes some thirty cases and Piart (These de Paris, 1896,) also has discussed the subject. The blood supply of the pleuræ is rich. The visceral pleura is supplied by the bronchial artery, the diaphragmatic and costal pleuræ by the diaphragmatic and intercostal arteries and the mediastinal pleura by the superior diaphragmatic, the internal mammary, the bronchial and the superior mediastinal arteries. It is to be believed that gonorrhœal particles reach the pleuræ and lungs through the circulation and not through inspired floating matter in the air, and that these cases are local manifestations of a general systemic gonorrhœal infection.

Bordoni Uffreduzzi (Deut. med. Woch. 31 Mai, 1894, 484,) reports two cases of gonorrhœal pleurisy, one in a woman with arthritis showing gonococci in the pus from the joints; another in a girl of eleven years, in which polyarthritis followed an old double pleurisy,

the fluid of which showed gonococci on aspiration. Following these there was endo-pericarditis which subsided and which were undoubtedly of gonorrheal origin.

Chiaiso et Irnardi (Giornale della R. Acad. di Med. di Tor. Fev. 1894, 93,) observed a case in a girl of ten with gonorrheal rheumatism of the feet, knees, right shoulder and wrists. A systolic mitral murmur appeared and persisted. The puncture of a right pleural effusion showed fluid containing the gonococcus.

But pleurisy may result from supposedly ordinary cases of gonorrhea as is shown by a case of Ahman (Arch. f. Dermat. u. Syph. 1897, xxix, 323,) in which the urethra of a healthy man was inoculated with the culture of the fifth generation of cocci from a case. In spite of every precaution cystitis, epididymitis, synovitis and pleurisy resulted.

Pneumonitis.

Schlagenhauser (*op. cit.*), in an interesting case of gonorrheal ophthalmia, arthritis and phlegmon complicated with pneumonia, found typical gonococci, together with the streptococcus pyogenes and the diplococcus pneumoniae in the sputum. Post-mortem the pulmonary alveoli were found to be distended with exudate composed of red blood corpuscles, epithelial cells and pus corpuscles containing gonococci.

In another case observed by Krause (*op. cit.*), a case of acute gonorrhea became complicated by endocarditis, pleurisy with effusion, and five weeks after the occurrence of the initial symptoms showed the gonococcus in the blood by culture. Post-mortem this case

showed acute fibrinous pericarditis, gonorrhoeal ulcerative aortic endocarditis, fatty degeneration of the myocardium, pleurisy with effusion, ascites and lobar pneumonia. The gonococcus was found in pure culture in the pulmonary alveoli.

Another case of gonococcus pneumonia is reported by Bressel (*Munch. med. Woch. Mch.* 31, 1903,) in which a patient with acute gonorrhoeal urethritis developed pneumonia, the sputum showing the characteristic intra-cellular organisms, and the peripheral blood giving a positive culture of the gonococcus. This interesting case made a good recovery.

Another unusual case of gonorrhoeal invasion of the respiratory mucous membrane is of interest. (Kimball, *Med. Rec.* lxiv, 765.) An infant of two and one-half months is admitted to the Babies' Hospital as a case of malnutrition. Father consumptive, mother well, child well for first month of life; nursed but two weeks; no ophthalmia, but considerable thrush in the mouth. Digestion and stools normal. There is progressive involvement of the joints,—first the left wrist, then both ankles, right knee and little finger, with fluctuation in all of these joints. The temperature is under 102° F. until the last three days of life, and during these is normal. Gonococcus in pure culture in the pus aspirated ante-mortem. Autopsy showed small abscesses under the scalp, under the skin over the chest, and between the larynx and the hyoid bone. There is pus in all the joints involved, and on incising the larynx pus containing gonococci is found in the posterior wall between the mucous membrane and the thyroid cartilages. Incipient broncho pneumonia. No gonococci in the eyes or urethra.

Gonorrheal Endocarditis.

Gonorrheal endocarditis probably results from the presence of gonococci in the blood stream and their engraftment upon the cardiac valves, especially upon the lesions of an old endocarditis, by the impact of the valves. Once established, an infected valve acts as a point of distribution for the infection of the whole system.

As early as 1854 Brandes (Arch. gen. de Med. xciv, 257,) called attention to this complication, and in 1872 Lacassagne (Arch. gen. de Med. cxxix, 15,) stated that gonorrhea might attack any serous surface, and that gonorrheal affections of the peri-endo and myocardium were not infrequent. In 1872 Martin (Rev. Med. de la Suisse Romnade, 1872, ii, 308,) observed a case of gonorrhea complicated by suppurative prostatitis, cystitis, ulcerative endocarditis, abscesses of the myocardium and metastatic abscesses of the kidneys. Characteristic diplococci were found. His (Deut. med. Woch. xxix, 1892, 993,) Leyden (Zeit. f. klin. Med. xxi, 607,) Winderberg (Fest. Jub. der Vereins deut. Aertze, San Francisco, 1894,) Michaelis (Zeit. f. klin. Med. xxix, 556,) Lartigan (Am. J. Med. Sci. cxxi, 52,) also have reported interesting cases in which the gonococcus was found on the heart valves. In fifty-nine cases of malignant endocarditis observed by Jackson (Bost. City Hospt. Rpts. xi, 67,) three were gonorrheal.

For brevity's sake it must be said that endocarditis of gonorrheal origin does not differ symptomatically from that caused by other organisms. The presence of an active or even subacute gonorrheal urethritis,

gonorrhœal prostatitis or prostatic abscess, and especially a gonorrhœal arthritis,—would warrant the prediction that an endocarditis, more especially of the ulcerative or malignant form, was gonorrhœal in its nature.

Pathology.—This varies with different cases,—there may be round or irregular ulcerations which are shallow, surrounded by a ring of pearly lustre, varying in size from minute punctate spots to large areas covering one or more valves. If these are deep enough the valves are perforated, or the endocardium may be undermined. In the vegetative form pedunculated, pyramidal or verrucose masses proceed from the valve, which show a microscopic structure of connective tissue reticulum filled with blood platelets and leucocytes. Further particulars are readily found in the abundant literature on the subject,—and in discussion of the pathology of gonorrhœal endocarditis in particular, the attention is invited to the following condensed autopsy reports.

Thayer & Blumer. (Jhns. Hopk. Hospt. Bull. vii, No. 61, 57.) A woman of thirty-four, short of breath for four years, five months ago had fugitive pains. Malaise increasing into prostration, herpes on lower lip, thirst, anorexia, chills and irregular temperature, are the chief symptoms. Heart shows presystolic murmur followed by a blowing systolic sound at the mitral area transmitted into the axilla. Leucocytosis of 12,000. Post-mortem,—vegetations consisting of red pedunculated mass and red blood corpuscles measuring 2 by 3 cm. from mitral valve: valve eroded under the vegetations. Microscopically the valves show subacute endocarditis,—infiltration of valve

substance with large numbers of polymorphonuclear leucocytes and a few round cells and mastzellen throughout the inflammatory areas. Gonococci are found in small numbers in sections, but in large numbers on the margins of the valvular growths. Smears from the valves show the invasion of the nuclei as well as the protoplasm of the pus corpuscles by the gonococci, — a very rare condition never observed by the writer. Blood cultures were taken three times during life and were twice found in pure culture and growing readily on blood serum.

Case of gonorrheal endo-myo-pericarditis. Councilman. (Bost. City Hospt. Rpts. Series v, 55.) Man noticed urethral discharge four weeks before entrance to hospital; ten days later left knee becomes involved and three days later the other; the inflammation then rapidly extends to the ankles, fingers and shoulders. Slight pain in the chest, — examination shows slight increase in the area of heart dulness but no friction sounds or cardiac murmur, and on the day before the patient's death this pain became so severe that leeches were applied. Sudden death without premonitory symptoms, the pulse having been below 110°, and the temperature not having arisen above 99.5° F. Total duration of illness about 5 weeks.

Post-mortem. — Lower portions of both lungs edematous; both lungs free from adhesions but compressed by the pericardial sac which is enormously distended, containing 800 cc. of hemorrhagic exudate with masses of clotted blood. Myocardium of left ventricle firm and of waxy color resembling amyloid. Near endocardium at the bases of the papillary muscles

the tissue has a translucent and gelatinous appearance, and this tissue extends into the myocardium for a considerable distance. This condition of the myocardium is confined almost entirely to the left ventricle. On the anterior surface of the left auricle there is an area 2 by 3.5 cm. where the muscular tissue is changed into a pale opaque material which in some places is soft and almost broken down. The follicles of the intestines are enlarged and hyperemic and in some places appear like small polypi: all mesenteric lymph glands are enlarged. The right knee joint is greatly distended and on section 100 cc. of gelatinous, stringy and rather transparent pus escapes. The muscles above the joint show diffuse purulent infiltration. The synovial membrane of the joint is swollen and intensely congested, and projecting into the joint are fungoid masses presenting the appearances of tubercular granulations. Sections of the heart showed the most intense pericarditis, the pericardium being everywhere thickened, in some places to 3 mm. In the thickened pericardium there are numerous widely dilated blood vessels, from which the blood in the sac probably proceeded, and the tissue is loose and infiltrated with pus cells. In the myocardium all grades of change from infiltration to necrosis and suppuration involving the entire thickness of the heart wall can be observed. Gonococci were found in the fluids from the urethra, the seminal ducts, the knee joints, and in sections of the myocardium, the pericardium, and the knee joints.

Rendu & Hallé (Bull. et Mem. du Soc. Med. des Hop, de Paris, 1897, xiv, 1325,) report an interesting case of gonorrhœal endocarditis in which the coccus

was found in pure culture in the endometrium during life and from the elbow joint and heart lesion post-mortem.

Gonorrhœa may be the indirect cause of endo-myocarditis as is illustrated by the following case of Weckerle. (Munch. med. Woch. 1886, Nos. 32 to 36.) Robust woman of twenty-one years: gonorrhœa, right inguinal adenitis, articular symptoms resembling acute articular rheumatism. Two weeks later systolic murmur develops at apex, right-sided pleurisy with dilatation of the right heart and acute nephritis leads to her death.

Post-mortem. — Ulcerative *pulmonary* endocarditis, dilatation of the right heart, atrophic myocarditis, embolism of arteries of inferior lobes of both lungs, right pleurisy, parenchymatous nephritis. The myocardium kidneys and the vegetations on the valves showed cocci in chains and masses which were considered by Finger as non-gonorrhœal. Quite likely this case is representative of a considerable number of cases of malignant endocarditis in which the gonococcus was not found post-mortem, but which owed their existence to bacteria admitted with the gonococcus at the time of original infection or gaining admission through gonorrhœal lesions.

Phlebitis.

Gonococci find their way to the intima of blood vessels by direct deposition from the blood stream, and by penetration of the walls from surrounding infected tissue. In consideration of the traumatism which we know occasionally accompanies instrumenta-

tion of the urethra, it is not surprising that bacteria are forced through vessel tunics and set up a vasculitis. Gonorrheal phlebitis is not common,—but twenty-six cases are thus far available. As might be supposed phlebitis is a feature of the complications of gonorrhea rather than of the primary urethritis itself. Heller's case (Berl. klin. Woch. No. 28, 1904, 610,) was caused by prostatitis and severe urethrocystitis: cases recorded by Batut (Gaz. hebdom. 1900, No. 54,) Stordeur (Prog. med. Belg. Juni, 1900,) Tedenat, Fouilloux, Martel and Sasserath (Inaug. Dis. 12 März, 1904,) were secondary to epididymitis. A case reported by French-Banham (Lancet, Oct. 16, 1886,) had gonorrheal pleurisy, prostatitis and pyelitis, and one of Martel (These Paris, 1887,) had gonorrheal erythema nodosum.

In this series of twenty-six cases the phlebitis was right-sided sixteen times, left in fifteen, and in thirteen the side was not specified. Of these forty-four involvements the distribution was among the following veins:—common iliac, femoral, popliteal, profunda crurae, internal and posterior saphenous, superficial abdominal, vaginal, dorsal of penis, corpora cavernosa, prostatic and vesical plexus, pampiniform plexus, upper arm forearm. That gonorrheal phlebitis is quite as serious as that caused by other organisms, appears in that in one of these cases amputation of the thigh for popliteal and femoral phlebitis was necessary: in another fatal pulmonary embolism ensued; in another general pyemia with death resulted; in one thrombosis of the cavernous, prostatic and vesical plexuses occurred; and in one gangrene of the penis from thrombosis of the veins of the corpus cavernosus took place.

Additional features of gonorrheal phlebitis will be noted in the discussion of general systemic infection.

Arteritis.

Arterial thrombosis of distinctly gonorrheal origin is so uncommon that a brief abstract of a case of Moore is given. (Lancet, Dec. 19, 1903.) The post-mortem of a case of dry gangrene of both legs following acute urethritis showed a firm reddish-gray coagulum filling the aorta below the renal branches, — another of the left renal artery extending into the divisions of the hilum, and another extending from the pelvic brim down the external iliac to the common femoral artery. There was also necrosis of the left kidney caused by the thrombosis of the renal artery. Histological examination of the thrombus showed gonococci in its substance and in some portions of the vessel a complete disappearance of the intima. Besides the urethritis two tiny foci of suppuration were found in the prostate gland, and it is to be supposed that these contributed the infectious particles which caused the thrombosis.

General Gonorrheal Infection.

The following features of general gonorrheal infection have already been discussed under various headings:—endocarditis, a cause as well as a result of general infection; blood cultures in arthritis and under the bacteriology of the gonococcus; phlebitis and prostatic abscess causing pyemia; instrumentation as a means of admitting bacteria to the circulation. In addition to these, however, several cases are of

great significance, and serve to illustrate not only the direct but the indirect results of gonorrhœal infection, *i. e.*, mixed infections due to gonorrhœal urethritis.

Hallé (Ann. de Gyn. Sept. 1899,) reports a case of a woman who acquires gonorrhœa which assumes the hemorrhagic form of metritis. Suppurative peri-arthritis of the elbow then ensues and the patient advances into a state of hectic fever with rapidly developing gonorrhœal aortic endocarditis. This assumes the malignant form and is rapidly fatal. Post-mortem, — the gonococcus is found in the uterus, in the periarthritic pus and on the aortic vegetations.

General pyemia with multiple foci of suppuration is very well illustrated by the unusual case of Finger (Arch. f. Derm. u. Syph. Wien. u. Leip. xxviii, 1894.) A child with gonorrhœal ophthalmia develops arthritis, in which the cocci are found in pure culture, and this is followed by extensive phlegmonous inflammation of the neck and mediastinum causing death. Post-mortem, — gonococci are found in the right articulation of the jaw, in an area of perichondritis about a sterno-costal articulation, gonococci and streptococci and in a peri-articular abscess of the left thigh, and streptococci alone in the left articulation of the jaw and in the phlegmons of the neck and mediastinum.

General infection and death may follow with startling rapidity as has been observed by Osler (Practise, 256.) Severe chills gave place to high temperature, unconsciousness and profound toxemia. Death occurred ten days after the first appearance of the gonorrhœal urethritis. Post-mortem showed acute gonorrhœal urethritis, a small prostatic abscess 3 cm. in diameter and a peculiar tarry condition of the blood.

Ullmann observed five cases of gonorrheal sepsis, all fatal and all but one with prostatic abscesses. (Deut. Arch. f. klin. Med. lxi, 309.) i. Untreated gonorrhea for several months, prostatic abscess showing no symptoms and being unrecognized during life, septic thrombosis of prostatic plexus and general pyemia from this. ii. General infection, the symptoms resembling typhoid, staphylococcus abscess of the prostate of gonorrheal origin. iii. Gonorrhea followed by periorchitic and prostatic abscesses, the latter not recognized during life. iv. Prostatic abscess followed by cystitis and pyemia. v. Gonorrheal arthritis followed by gonorrheal pericarditis and ulcerative endocarditis and general sepsis.

But the finding of the gonococcus in the blood does not necessarily mean that death will result, for Krause (Berl. klin. Woch. May 9, 1904,) observed such a case in a woman who became infected through a laceration of the perineum and developed double gonorrheal pyosalpinx. General infection in this case was evidenced by enlargement of the spleen, pain and swelling of the knee, along the course of several ribs, and by a positive culture from the blood.

Another interesting case of general infection with recovery was observed by Breton (J. des Mal. Cut. et Syph, 1894.) In a young man of twenty-one, enlargement of the spleen and inguinal glands announces the general character of the infection: this is followed by acute endocarditis, multiple peri-arthritis and a polymorphous erythema which is first macular, then papular and then followed by the formation of vesicles containing gonococci.

Another case of neglected gonorrhœa is described by Pollard (*Lancet*, May 30, 1885.) A woman of 19 years has gonorrhœal vaginitis for 36 days. Autopsy shows pus in the knee and hip joints, the articular cartilages are eroded, and there is embolism of the left common iliac, the internal iliac and the vaginal veins.

V.

SEQUALE PECULIAR TO THE MALE.

The Part Played by the Prostate in Gonorrhoeal Disease.

A BRIEF review of the topographical, gross and microscopic anatomy of the prostate readily shows its great importance in septic conditions of the urethra. It is a compound tubular gland, supported by a framework of connective tissue and involuntary muscle fibre. The glands are arranged radially around the urethra and their ducts open into the prostatic sinuses on either side of the verumontanum. They are 30 to 40 in number and are lined by a single layer of columnar epithelium. Inmeshed in the glandular walls are the lymphatics which follow the veins of the prostatic plexus and end in the internal iliac lymphatic nodes. The whole prostate is enveloped in a fibrous capsule which is formed by a condensation of the stroma of the gland itself and is distinct from the retro-vesical layer of the pelvic fascia. Between this investment and the pelvic fascia is the prostatic plexus of veins which lies on the anterior and lateral aspects of the gland. This disposition of the fascia is to be regarded as the fortunate provision against the invasion of the pelvic peritoneum by septic organisms from urethral

and prostatic suppurations. The position of the prostatic plexus therefore is such as to render it more liable to injury by instrumentation than if it were posterior to the gland. The prostate is pierced by the ejaculatory ducts and the urethra, and it receives infection from the urethra and in turn communicates the same to the seminal vesicles.

Prostatic involvement in gonorrhœa is very common indeed. In 400 cases of gonorrhœa Colombini (Giorn. Ital. delle Mal. Ven, 1896, No. 5,) found that 33% had involvement of the prostate, seminal vesicles and vas deferens. Of these 160 were acute cases of which 32 had prostatitis, and 15 prostatitis and seminal vesiculitis; 180 were subacute with 35 complicated by prostatitis and 4 by seminal vesiculitis; 60 were chronic with 21 of prostatitis and 3 with vesiculitis. In 190 cases Poehl found the prostate involved in 39.7%. Montagnon and Eraud consider that 70% of all cases invade the posterior urethra.

Prostatic involvement does not usually occur before the third week of infection, but may begin much earlier if there is instrumentation.

Pathology.—The pathology of acute and chronic prostatitis resembles that already described as common to gonorrhœal infection of Cowper's, Bartholini's, Skene's and other glands. There is at first acute congestion which follows immediately on the invasion of the follicles by the bacteria. The next step is that of acute folliculitis with infiltration of the epithelium, local leucocytosis, destruction of cells, desquamation, the formation of phlegmonous nodules which may resolve or continue on to the formation of small

abscesses. The process may be limited to small radicles or continue by continuity of tissue and involve the parenchyma of the organ. With this there is great destruction of tissue, and the formation of multiple or single abscesses, of varying size, which may rupture into the urethra or may form channels in the path of the least resistance through the fascia already described. In 102 cases of suppurative prostatitis observed by Finger, 64 ruptured into the urethra, 43 into the rectum, 8 into the ischio-rectal fossa, in 3 inguinal abscesses formed, in 2 pus escaped through the obturator foramen, in 1 through the umbilicus, 1 case through the sciatic foramen, in 1 it escaped at the border of the false ribs, in 1 into the abdominal cavity and one into the space of Retzius.

An important contribution to the pathology of this condition is made by Young (*op. cit.*) who found the gonococcus together with the *B. coli* in fluid aspirated from the bladder in a case of abscesses and perineal fistula following stricture. In this case there were multiple abscess cavities and sinuses and the tissue was transformed into a spongy but firm mass not easily torn, consisting of a fine fibrous stroma from the meshes of which yellowish-brown pus could be pressed.

Coincident with suppurative conditions of the prostate there is frequently infectious phlebitis of the prostatic plexus, the anatomy of which has already been alluded to. The usual features of phlebitis are observed on dissection and microscopical examination. The prostate is enlarged, elastic and painful on palpation, the vessels are indurated and cord-like. Section shows thrombosis from the filling of the lumen of the

veins with coagulum which soon becomes septic, the vessel wall may ulcerate, rupture occurs with the outpouring of septic materials, and localized abscesses form which may burrow in the directions already noted. Embolism from prostatic thrombo-phlebitis readily occurs and general infection may result. In elderly men there is frequently a dilated condition of the veins of this plexus, the valves atrophy and fail to fill their function thereby increasing the possibilities of embolism.

Attention is called to the representative photomicrographs of sections made by the writer in the study of the pathology of gonorrhoeal disease of the prostate, representing the stages of degeneration from the normal, to that of total destruction of prostatic tissue.

The Rôle of Gonorrhœa in the Etiology of Prostatic Hypertrophy.

All cases of prostatic hypertrophy may be divided into two classes, the first in which the increase in size is due to a tumor formation such as fibromyoma, fibroadenoma or adenomyoma; the second in which there is general increase in the size of the organ without tumor formation and with increase of connective tissue. The most complete and exhaustive study of this problem has been made by Ciechanowski (Mittheilungen aus den Grenzgebietender Med. u. Chir. Jena, 1900,) who concludes that prostatic hypertrophy of the aged is an inflammatory disease and that previous urethritis must be held accountable for the majority of cases. He considers that the variety of the hypertrophy is determined by the primary locus of inflam-

mation, and if this be near the periphery of the prostate a marked increase of connective tissue will take place resulting in the hard variety. If the inflammation starts centrally around the ducts, the large, soft prostate resembling an adenoma is formed. These studies were confirmed by Brooks (Jnl. Am. Med. Assn. Sect. on Surg. 1901, 420,) in the examination of thirty prostates. These views are disputed by Keyes (Jnl. Am. Med. Assn. July 16, 1904, 187,) who, in an examination of 433 cases of prostatic hypertrophy found evidences of previous prostatitis in but eighteen. In these there were no marked differentiating features and he finds that continued prostatitis tends to cause atrophy rather than hypertrophy.

Symptoms of Prostatitis.—These vary from absence of pain with no systemic disturbance, to chills, high temperature and pulse, nausea and vomiting, delirium and typhoid state. There may be intense pain in the prostatic region, rectal palpation may be impossible, there may be tenesmus, hematuria, pyuria and polyuria. On account of several cases of prostatitis which have been proved the cause of general infection, it is of great importance, in post-mortem examinations, to incise the prostate in parallel planes, that all parts of its mass may be inspected.

Epididymitis and Orchitis.

These are among the most frequent of all complications in the male and usually result from the direct extension of urethral and prostatic inflammation by continuity of mucous membrane. Gross, Engelmann and Brothers place the ratio as 17%, 20% and 25%

of all cases of gonorrhœal urethritis. In 28,787 cases of gonorrhœa Neisser found epididymitis in 27.1% and other complications in 17.8%. In the analysis of 285,048 cases, Morrow (Social Diseases and Marriage, 155,) found epididymitis in 16.11%.

Finger observed 548 cases of epididymitis in 1,844 of urethritis, and in 3,136 cases compiled by him 1,500 were right sided, 1,425 were left and 211 were double.

Pathology. — Gonococci enter the duct and vas from the urethra and invading the epithelium cause cloudy swelling, desquamation, infiltration of the walls, small celled infiltration of the pericanalicular tissue, proliferation of connective tissue, liquefaction of inflammatory products and suppuration. If abscess forms, incision reveals crumbly curdy pus and masses of yellow shreds — the coils of tubules which may be teased out with needles. Such abscesses may be multiple and coalesce forming a large sac with almost complete destruction of the testicle, or they may be limited by the septa of the tunica albuginea to one or several lobules. Gonococci may proceed through the epididymis and invade the tunica albuginea and vaginalis testis causing hydrocele which is serious or purulent according to the extent of the inflammation. The rupture of an abscess of a lobule into the tunica vaginalis is also a cause of suppurative hydrocele and an inflamed epididymis may become adherent to a pre-existing varicocele and infect the sac by transudation. The inflammation may be limited to the vas, causing a true cordonitis in which the spermatic cord can be traced to the external inguinal ring externally, and by the rectum, as a hard elastic cord, to the prostate.

The rupture of an abscess of the vas or seminal vesicles into the peritoneum occurs in rare instances and will be referred to in the discussion of peritonitis of the male.

Gonorrhœal Disease of the Seminal Vesicles.

Finger (Internat. klin. Rundschau. Wien. Feb. 12, 1893,) was one of the first to call attention to this complication of gonorrhœa, and later observers have shown the commonness of the infection. The frequency of prostatic involvement in urethritis easily accounts for the infection of the ejaculatory ducts and vesicles by continuity of epithelium. Again we note the similarity between the anatomy and pathology of the male and female tubules which might be predicted from the embryology. In the male the vesicles and ducts and the head of the epididymis are formed from the canals and duct of the Wolffian body, while in the female the Fallopian tube is developed from the duct of Müller, a duct quite analogous with the Wolffian, being the efferent tube of a contiguous segmental organ. Microscopically, the structure of the folds of this tubular organ, and of its inflammations very closely resembles that of the Fallopian tubes. The first stage of inflammation consists in congestion of the mucosa followed by small celled infiltration. This difference, however, exists between this stage of inflammation of the vesicles and the tubes, — the substance of the folds of the latter is much more readily invaded than is the stroma of the prostate and the rugae of the seminal ducts. This is probably due to the compact non-vascular, fibrous structure of the latter. The next stage is that of des-

quamation of epithelium which continues until there is left only a framework such as is illustrated in the photomicrograph of gonorrhœal abscess of the prostate. The figure illustrates the first stage of gonorrhœal inflammation of the seminal vesicle, and this section is selected for photography from a large number of preparations as illustrative of both normal and infected rugae. In the upper part of the field it will be observed that the contour of the gland-like acini is distinct and the epithelium quite uniform in thickness. Towards the free surface, however, the contour is not sharp owing to disintegration of the epithelium and the accretion of pus. In the lower portion of the field all semblance of normal structure is lost, — the folds are matted together and with a hand-glass the corpuscular character of the almost homogenous mass can be distinguished. With a later stage of inflammation there is complete destruction of the mucosa, in places it remains adherent to the stroma and tube walls, at other parts it is entirely wanting and nothing but a few pus corpuscles remain. As a rule there is but little invasion of the surrounding structures, the fibrous investment serving as does the stroma and capsule of the prostate, as an almost impenetrable barrier to the suppurative process.

In gonorrhœal disease of the seminal vesicles we find another important cause of sterility in the male. Normal and vigorous spermatozoa may be formed in the tubules, but when surrounded by the contents of a gonorrhœal vesicle, they are soon attacked by bacteria and lose their vitality and structure. In the writer's studies, smears were made of the contents of the vesicles before fixing and mounting for section cutting, in

order to observe the character of the desquamated epithelium, and it is not infrequently that the vestiges of spermatozoa, detached flagellae and epithelial cells may be observed in all stages of disintegration, often with bacteria and gonococci imbedded in their substance.

We have described the various stages of gonorrhoeal inflammation of the prostate gland from its invasion to that of destruction of tissue with only vestiges of structure, and have considered it typical of gonorrhoeal inflammation of the tubes and ovaries. The analogy is applicable also to the seminal vesicles and their ducts. The vesicle becomes a septic sac, there is wholesale desquamation of epithelium and after resolution the secreting surface is so reduced that there is loss and even absence of the normal secretion upon which the motility and the migration of the spermatozoa depends. The present state of our knowledge does not warrant any statement as to the regeneration of this epithelium after gonorrhoeal disease.

Symptoms.—The symptoms of acute gonorrhoeal seminal vesiculitis are first those of posterior urethritis. There may then be any or all of the following symptoms: pain in the supra-public regions of either or both sides, which radiates into the hypogastrium or into the testicles; chills and rise of temperature; rectal examination shows tenderness and swelling of the vesicles, edema and tumefaction and infiltration of the perivesicular tissue often presenting a mass the size of an egg. This mass may be continuous with the prostate and there may be infection of the spermatic cord. The appearance of pus in the urine is variable, and may

occur at the onset of the attack or may not appear until the temperature and symptoms begin to decline, and then shows up in large quantities.

Sequale of Minor Importance, Balanitis, Cowperitis, etc.

Phimosis, balanitis and posthitis of gonorrhœal origin may exist without urethritis. In a recent case of this nature treated by the writer, there was presented the seeming anomaly of gonorrhœa with typical pus corpuscles enclosing cocci, but without urethritis. There was an advanced degree of phimosis and the exudate proceeded from the modified integument. Notwithstanding the facility with which local applications may be applied, these are often cases of great chronicity on account of the mucous follicles and paraurethral glands which offer material for auto-reinfection. The pathology of all these conditions is that of inflammation, congestion and infiltration of the integument, local necrosis with superficial desquamation, leaving ulcers over which there may be a croupous deposit of exfoliated epithelium and pus corpuscles containing gonococci.

Periurethral abscess has already been alluded to and is an example of the penetrating power of the coccus, so stoutly denied by Bumm and so ably demonstrated by Wertheim. Were the process continuous with the urethritis, the incision of such an abscess would usually be followed by urinary fistula as well as by a purulent gonorrhœal discharge from the urethra through the wound. Such a condition is fortunately rare and results only from too deep an incision or from delay in operating. The extent of periurethral abscesses is

markedly limited by the fortunate disposition of the septum pectiniforme and the trabeculae, fibrous barriers which are practically immune from inflammation.

Cowperitis usually appears in the third or fourth week after urethral infection and is due to extension from the urethra. It appears as a small, hard, painful tumor in the middle of the perineum. There is usually great pain on urination on account of the compressor urethrae muscle which encircles the gland. The gland often suppurates and ruptures into the urethra or perineum, — when into the former the condition is long lasting on account of contamination. The anatomical topography of these glands shows several reasons for these conditions. Situated under the urethra, their ducts pointing upwards, surrounded by the compressor urethrae, which prevents physiological rest by its increased action in tenesmus, it is easy to see how readily they may become infected, and once infected there is no provision for drainage by gravity; the glands are transformed into septic cisterns, which fill up, overflow and yet are not drained away. With rupture into the perineum or evacuation by incision, gravitational drainage is provided, and prompt resolution usually takes place.

Gonorrhoeal Peritonitis in the Male.

In the male the absence of channels of comparatively free communication between the peritoneum and the genitalia is to be noted. But, from the brief descriptions already given of the divers ways in which purulent foci may discharge and burrow, it is not to

be wondered that extra peritoneal abscesses occasionally burst into the peritoneal cavity and cause localized or general peritonitis. Cases of gonorrhœal peritonitis in the male are on record from the internal rupture of perinephritic abscesses, of mesenteric lymph nodes, of prostatic abscesses, of thrombo-phlebitis of vesical plexus accumulations.

The bacteriology of cases occurring in men has not been worked up as carefully as cases occurring in women, and nearly all recorded cases are open to the objections which attend any effort to trace infections without more complete data. The works of Fauçon (Arch. gende Med. 1877,) and Zeissl (Ann. des Mal. Genito-Urinaires, July, 1893,) are, however, prophetic and suggest that with modern bacteriological methods cases of this kind will be much more frequently observed.

Schepelern reports a case of a sailor who suffered for three weeks with gonorrhœal urethritis and after eight days of epididymitis was suddenly attacked by right-sided peritonitis and died in thirty-six hours.

Rougon (Finger, *op. cit.*) (L'Union Med. 1876, 651,) observed a case in a man of thirty-five who was moribund when brought to hospital for treatment, with small thready pulse, nausea and vomiting of bile, the abdomen painful and distended, right epididymitis and acute hydrocele. At autopsy the abdomen is found distended with gas, the peritoneum is covered with a croupous exudate which is thickest in the right iliac fossa, there is 300 cc. of sero-purulent fluid in the pelvis and iliac fossa, and 100 cc. of similar fluid in the right tunical vaginalis testis, the serous membrane being injected and bearing a croupous membrane.

The right epididymis is swollen, reddened, ecchymotic and containing foci of pus. The right spermatic cord is thickened and its investments show inflammatory exudation.

In the writer's opinion the case so completely reported by McCosh (*Ann. Surg.* xxi, 140,) cannot be classed among those of gonorrheal origin, as there is no evidence that the patient had gonorrhea or that the lesions were of this nature.

It does not necessarily follow that gonorrheal peritonitis always goes on to suppuration and require abdominal section any more than peritonitis caused by other bacteria. This is illustrated by a case reported by Brewer (*Ann. Surg.* xxxiii, 600,) in which a man of twenty affected with gonorrheal urethritis is suddenly taken with paroxysmal pain in the abdomen which soon becomes localized in the right lower quadrant. The abdomen is enlarged, hard and exquisitely tender. Palpation shows enlargement of the lymph glands along the right iliac vessels and by rectum the prostate is found to be enlarged and tender and from it there proceed a chain of nodes leading upwards. The treatment of the urethral and prostatic conditions is followed by the disappearance of the abdominal symptoms. Cases such as this are of important clinical application and suggest delay in operation until phenomena develop which allow a more complete interpretation of the abdominal symptoms.

VI.

SEQUELAE PECULIAR TO THE FEMALE.

Vaginitis.

It has been claimed by Bumm that the gonococcus was incapable of causing vaginitis, but his views are strenuously opposed by Schwartz who has found gonococci in the deepest layers of the mucosa and has observed cases of gonorrhoeal vaginitis in which the uterus, urethra and vestibule were entirely free from disease. Sanger finds that the unabraded vagina is not likely to be invaded by the gonococcus, but experiments on the human subject (See, *op. cit.*) prove conclusively that it not only may exist, but that it may persist and be stubborn in its resistance to treatment. The following are those factors which most commonly predispose to gonorrhoeal vaginitis:—previously existing vaginitis caused by other organisms, irritating discharges from the endometrium, mixed infection, traumatism of any kind but particularly that incident to parturition.

Without prompt and appropriate treatment nearly all cases of gonorrhoeal vaginitis pass into the chronic state. In fourteen cases studied by Rudsley (Medizinsko Obozryenie, Moskow, xlii, 934,) all were characterized by their tedious course, profound anemia, urethral

involvement and eczema of the vulva caused by the purulent discharge.

Pathology.—Edema and infiltration of the introitus, thickening and infiltration of the folds of the mucous membrane; there may be desquamation of epithelium with the formation of deep red angry-looking erosions which bleed on the slightest touch. The gonorrhœal vaginitis of pregnancy is occasionally seen in which the mucous membrane is transformed into a granulating surface and the folds covered with red papillary granules, — the so-called vaginitis granulosa.

Vaginismus may exist with vaginitis or be a sequel to it.

Atresia may follow gonorrhœal vaginitis, — the writer has observed one case, and Eberlin (*Zeit. f. Geb. u. Gyn.* xl, Heft 1,) notes two cases in which operation was necessary.

Gonorrhœal vaginitis predisposes to a peculiar fibrous degeneration called xerosis vaginae, in which there is thickening and rigidity of the thickened mucus membrane, the follicles become destroyed and the epithelium becomes devitalized and whitened, a condition sometimes called psoriasis mucosae.

Stricture of the Urethra in the male is a very common sequel of gonorrhœal urethritis and this subject has been so well covered in literature and monographs, particularly that of Otis, that it need not be discussed here. That stricture of the female urethra also is of comparatively frequent occurrence is not so well known, and it is to be noted that gonorrhœa is the most common cause of this disease in young and middle aged

women. Herman (Trans. London Obst. Soc. 1887, 43,) publishes a table of twenty-eight cases in which seven were of gonorrhœal origin. He describes others which were due to caustics employed in treatment.

Inflammation of *Skene's Glands* is very commonly if not always of gonorrhœal origin. These glands lie in the connective tissue of the vestibule and their ducts enter the urethral floor just within the meatus. In 100 cases of gonorrhœal urethritis Pollak (Zent. f. Gyn. 1903, ix,) found these glands involved in 45%. Of these 68% were of one gland and the remainder were bilateral. His studies showed that the ducts of these glands frequently contained gonococci long after their disappearance from all other parts of the genital tract and that in this way they are a frequent source of auto-reinfection.

Bartholinitis is one of the most common external manifestations of gonorrhœal vaginitis and urethritis. The bacteria invade the efferent duct which soon becomes occluded by the inflammatory thickening of its epithelium and the infiltration of the surrounding tissues. The glandular tissue is next invaded, the sub-epithelial layer is penetrated, there is globular swelling of the gland from distension and if the cyst be not relieved by incision there may be infiltration of the surrounding cellular tissue. If pus breaks through the capsule of the gland without rupturing externally, extensive sinuses may form leading to the perineum, vagina or rectum. Surgery, by early incision, usually averts any such unnecessary complication by relieving tension and providing drainage. In a notable series

of studies Bumm has demonstrated all stages of glandular inflammation from the initiatory invasion of the acini to suppuration and destruction of tissue. Resolution may occur without suppuration if the infection be of a low grade of virulence.

Gonorrhœal Salpingitis.

The mechanical forces which favor involvement of the uterus and Fallopian tubes in bacterial disease have already been discussed. Although the tubes are plentifully supplied with blood vessels and lymphatics it is probable that the inoculation of the mucous membrane with particles from the uterine cavity is the first step in the inauguration of an inflammatory process. When salpingitis is once established, however, infection may spread through the lymphatics and blood vessels as has been observed by the writer as well as by Krause. (Monat. f. Geb. u. Gyn. xvi, 192.)

Gonorrhœal salpingitis is of greater frequency than is usually supposed, the number of cases depending directly upon the gonococcus being much greater than those in which the organism is found after operation or post-mortem, — and for the reasons already given. Andrews (Am. J. Obst. Feb. 1904, 177,) in 684 cases found 55% sterile, the gonococcus in 22%, staphylococci and streptococci in 10%, the pneumococcus in 2% and the *B. coli communis* in 2.5%. Schmitt (Zeit. f. Geb. u. Gyn. xxi,) finds that gonorrhœa extends to the uterus in 20% and to the tubes in 5% of cases. In 116 cases of purulent salpingitis Wertheim found 72 sterile, 32 showed the gonococcus, 6 the streptococcus and one the staphylococcus. In 43 cases of

pyosalpinx Kelley found 33 negative, the gonococcus in 7 and the *B. coli* in none.

Recent bacteriological studies have shown beyond cavil that the gonococcus can lie encysted or dormant in the tubal or ovarian tissue indefinitely, and this knowledge renders all the more complex the important question of the curability of gonorrhoea in the female. It is thus seen that a tube which may appear normal to the eye may on careful preparation show foci of gonococci, and it is for this reason that Doderlin urges the extirpation of both tubes, if one is known to be infected, — a teaching which is finding ready acceptance among progressive gynecologists.

Infantile salpingitis is undoubtedly a common disease. And it is to be believed that many cases of infantile gonorrhoea causing but few pelvic or abdominal symptoms in infancy and seemingly making good recoveries at the time, remain quiescent until puberty, then develop insidiously, causing obscure pelvic symptoms, salpingitis with the possibility of rupture of the sac and peritonitis. It must be remembered that the larger number of cases of infantile gonorrhoea occur in crowded tenement districts where children are herded together and where the sick have but little care unless seriously ill. Again, it is well known that it is next to impossible to impress upon the great majority of patients the importance of professional guidance and treatment after the acute symptoms are over, and most gonorrhoeal patients consult a physician only while there is pain or discharge. In the case of infants the gonococci may remain in the tubal walls or lumen until the time of first menstruation, the tubes then become congested, suitable culture medium is provided for

their multiplication and womanhood is burdened with pelvic disease from the first.

Bidwell and Carpenter (Br. J. Children's Diseases, Oct. 1904,) report two interesting cases :

I. A girl of six has purulent discharge from the vulva, superficial ulceration of external genitals, hematuria, painful swelling of the right foot with redness and edema over the flexor tendons, temperature 102° F. Incision evacuates clear fluid from the tendon sheath. Two weeks there is abdominal swelling and on celiotomy both tubes are found to be full of gonorrhoeal pus. The vaginal discharge persisting dilatation of the cervix with curettage of the uterus is performed and followed by prompt recovery.

II. A girl of three and one-half years, vaginal discharge for six weeks, rectal bimanual shows bilateral salpingitis. One month later one of the enlargements had subsided and in another month the pelvis was apparently free from disease.

Bidwell suggests curettage in all cases of uterine gonorrhoea as the most efficacious means of preventing tubal involvement. The writer would oppose such a procedure for the following reasons: The possibility that the tubes are already infected; the fact that gonorrhoeal endometritis is not always cured by curettage; the probability of increase and extension of the inflammatory process by the traumatism of operation.

Pathology.—As might be supposed from our knowledge of the source of infection, the course of salpingitis is from the lumen of the tube into its substance. The epithelium of the villous-like folds is first

attacked, the cells becoming invaded by gonococci which proceed into the sub-epithelial structure and cause local leucocytosis. There is immediately an outpouring of pus which does not differ microscopically from that of acute gonorrhoeal urethritis when taken in the early stage of tubal inflammation, but showing cellular detritus, eosinophiles and plasma cells if observed when the inflammatory process is well under way. The tubal folds soon become matted together, forming a shapeless mass with hardly a vestige of the original villous structure, and with the further progress of the process there is complete destruction of the membranous portion of the tube which is converted into putrescent sack if unruptured,—a necrotic slough if still further advanced in the bacterial process.

In the photomicrographs herewith presented the several stages of gonorrhoeal inflammation are illustrated. In the cases from which these specimens were taken the gonococcus was positively identified in the tubal exudate. It is occasionally possible to observe the gonococcus in the tissues, but the picture does not differ from those so frequently seen in text books. Brief descriptions accompany each photomicrograph.

In the examination of stained sections of gonorrhoeal tubes it does not appear that the infiltration decreases uniformly as views are taken at increasing distances from the epithelium, but rather that clearly defined strata of pus cells appear in the tissue, the substance around such masses being but sparsely involved. Nor does it appear that the infection proceeds by the blood vessels, as we have seen it does in gonorrhoeal prostatitis, so it is to be inferred that these strata represent foci favorable to the development of those gonococci

which have found their way into the tube substance by way of the lymphatics. These foci lie, for the most part, along the perimysium and in advanced cases the muscular layer is stratified with them. On coming to the peritoneal layer the picture of intense infiltration with polymorphonuclear and plasma cells is again observed. It would seem, therefore, that in gonorrhoeal salpingitis the inflammatory involvement is found in three zones, the membranous and peritoneal layers being the most intense while the intermediary is but partly affected.

It has hitherto been the opinion of investigators that the invasion of the substance of the villous folds of the tubal mucosa occurred after the penetration, destruction and desquamation of the epithelium by the gonoóoccus. The writer finds numerous sections which would seem to show that this is not always the case, and that the sub-epithelial connective tissue framework and even the deeper tissues of the tube may be infiltrated, enormously thickened and even disintegrated before there is any desquamation of the columnar cells. This may be interpreted in various ways. It may be that the coccus penetrates without leaving any apparent path and develops in the connective tissue of the villous fold before the lumen of the tube becomes filled with pus. It may be that invasion of the tube substance is by the lymphatics or peritoneum, instead of from the tubal lumen. Or it may be that cocci may enter at some minute epithelial denudation and penetrate deep into the fold by the minute lymphatic channels which may be demonstrated by suitable stains.

As a rule gonorrhoeal salpingitis pursues a slow

chronic course with occasional exacerbations. Occasionally, however, if the infection be of a particularly virulent generation, or if it be mixed, the suppurative process is very rapid and disintegration of the tube with fulminating peritonitis takes place.

Moskowicz (Cent. f. Gyn. 1899, 34,) reports an unusual case in which tubal pregnancy existed with a gonococcus and staphylococcus pyosalpinx.

Gonorrheal Ovaritis

is usually secondary to uterine and tubal gonorrhea and occurs with less frequency than gonorrheal salpingitis. Infection reaches the ovary from within,—by the blood vessels and lymphatics, and from without from the free peritoneal space. The veins of the pampiniform plexus which anastomose freely with the veins of the vagina and uterus are more likely to carry infection than are the arteries, which proceed from the aorta. Infection from the free peritoneal space occurs when there is a localized peritonitis in the vicinity of the ovary caused by leakage from a pus tube.

Pathology.—Congestion of the ovary is followed by infiltration of the stroma by serous or sero-fibrinous exudate which causes increase in its size. With this inflammatory swelling minute hemorrhages, take place both in substance of the ovary and on its surface, and these may be readily observed in sections. Bacterial deposits soon follow and the breaking down of such foci causes abscesses which vary from microscopic size to the involvement of the entire ovary. An ovarian

abscess may rupture into the peritoneal space causing localized or general peritonitis, or it may rupture into the tube, to which it has become agglutinated by inflammatory adhesions forming a tubo-ovarian abscess. Instead of causing abscess formation, the inflammation may progress very slowly and become chronic with contraction of the stroma which causes the compression and disappearance of the ovarian elements,—the cirrhotic ovary in which there is hardly a vestige of ovarian tissue.

Gonorrheal Endometritis.

The probability of uterine involvement in a case of vaginal or urethral gonorrhoea depends largely upon the condition of the cervix uteri. Normally the canal opens as a transverse slit, but one-twelfth of an inch in length and it is closed by the posterior vaginal wall against which the cervix rests. The canal is small, and if not previously dilated will just admit a sound of F 5 calibre. In multiparae, however, lacerations of the cervix are very frequently observed and the canal is often large enough to admit the finger tip, and is practically a continuation of the uterine cavity.

Occasionally fibrosis of the cervix or lower uterine segments imparts a rigidity to the cervical canal maintaining it as an open tube. It is in conditions such as these that gonorrhoeal endometritis is most commonly acquired and often without either vaginal or urethral infection. All such cases observed by the writer have been in multiparae with large open cervical canals readily admitting the little finger, a calibre of about 33 F.

Symptoms.—Tenderness of the uterus on bimanual which may be rectal or vaginal; agonizing uterine colic if there is cervical stenosis or extreme flexion; a uterine discharge which is at first bloody or sero-purulent and contains gonococci and which later becomes viscid and gelatinous containing few or no bacteria. These acute symptoms may be intense, the suffering great, the pulse and temperature high, or they may be so very slight as to cause but little physical discomfort. The acute stage passes off in from one to three weeks, and, in the subsequent period in which gonococci appear but occasionally in the discharge, it may be impossible to determine the gonorrhoeal nature of the disease.

Pathology.—The endometritis excited by the gonococcus does not differ in its characteristics from catarrhal inflammations of other epithelial surfaces. Infiltration of the several layers, destruction and desquamation of the epithelium and the covering of the inflamed surface with pus all take place. This may subside without deep involvement of the uterine tissue particularly if the organ is in its normal position, in which its cavity has the advantage of gravitational drainage, and the cervix is large and dilated. Very frequently, however, enhanced by those forces which favor gonorrhoeal conditions elsewhere, the glandular and deeper tissues are invaded and the condition becomes one of acute metritis,— a disease which is prone to pass into the chronic state. With this there is copious desquamation of epithelium and proliferation of connective tissue which may constrict the glandular and vascular elements causing villous excrescences of

great vascularity. With an advanced degree of inflammation there is almost complete destruction of the endometrium and the periglandular tissue becomes so infiltrated that its structure is completely obscured. With the deep involvement of the uterine tissue comes the invasion of the blood and lymph vessels, in which the uterus is particularly rich. In this case the uterus may serve as a nidus for the general distribution of the infection,—either by minute bacterial particles absorbed as such into the circulation, or by gonorrheal thrombo-phlebitis similar in its features to that described in the discussion of the gonorrheal involvement of the prostatic plexus. The enormously increased vascularity of the uterine mucosa in pregnancy and the puerperium, together with the increase in blood pressure and in the fibrin forming content of the blood at that time, particularly predispose to this pathological sequence. It is after gonorrheal endometritis that the uterine glands frequently undergo cystic degeneration with the formation of ovula Nabothi, appearing as minute vesicles in the mucous membrane.

Pelvic Abscess is very commonly of gonorrheal origin and originates most commonly as a complication of perimetritis after labor or abortion. In twenty-five cases of pelvic abscess Kelley found the gonococcus in four, the streptococcus in three, the colon bacillus in four, and twelve were sterile. This disease is so completely discussed in literature that no special mention is needed here.

Gonorrhœa Complicating Pregnancy.

Gonorrhœal endometritis, as a cause of sterility in the female has already been discussed as have also the anatomical obstacles to the upward progress of bacteria from the vagina during pregnancy. The inception of gonorrhœa during pregnancy presents an interesting problem upon which there are but few data. In 101 cases of gonorrhœa which became pregnant Fruehinsholz (Cent. f. Gyn. 1903, 45,) found that 71 went to term, 23 aborted, and 7 had premature labor. Williams believes that 73% of all abortions are due to endometritis of gonorrhœal origin, a percentage which seems unusually high. Noeggerath observed 19 abortions in 53 pregnancies acquired during the course of gonorrhœa.

Fruehinsholz believes that acute gonorrhœal urethritis does not prevent conception; 26% of the pregnant women in the Leipzig clinic were gonorrhœal. Oppenheimer found that 27% of the pregnant women at the gynecological clinic at Heidelberg had the disease and 40% of the children born at that institution had gonorrhœal ophthalmia. From these figures it is readily seen that the inception of gonorrhœa during pregnancy renders a large number of complications possible. That they do not occur more frequently is due to the fact that the fetal mass and the mucous plug in the cervix of the gravid uterus are effectual obstacles to the upward progress of bacteria. The rupture of the sac invites the entrance of vaginal organisms which immediately invade the uterine cavity and cause puerperal infection. With advancing pregnancy there is the possibility that latent or encysted gonorrhœal particles might be disturbed and cause febrile disturbances.

Complicating the Puerperium.

The puerperium offers distinctly favorable conditions for the various genito-urinary complications of gonorrhœal urethritis. The traumatic and etiological elements which combine to further the infection have been enumerated in the discussion of Mechanics of Gonorrhœal Infection. With the prediction that in the future it will be found that the gonococcus is concerned in a very large percentage of cases of puerperal infection, the attention is invited to very brief abstracts of cases and investigations.

Bumm (*op. cit.*) found large quantities of gonococci of large size in the lochia, two to five days after labor, and concludes that the conditions are particularly favorable for their development after labor.

Kronig (*Cent. f. Gyn.* 1893, No. 8, 157,) confirmed nine gonorrhœal puerperal cases by culture on Wertheim's medium. His findings as regards temperature are characteristic of gonorrhœal infections, one case running a normal temperature throughout convalescence which was not protracted, the rest varying from normal to 40.2° C. Of these cases two only had complication,—one a left-sided pelvic peritonitis with exudate, the other parametritis and tendo-vaginitis.

Sanger reports a case who acquired gonorrhœa nine days after labor which speedily caused pelvic peritonitis which lasted for twenty-two weeks. Also one in a woman who developed parametric infiltration the the third week after delivery of her sixth child, the infection being admitted by a laceration of the cervix.

Cumston reports several interesting cases. i. A woman of twenty-four years; 5 days after labor the

the temperature rose to 39° C., pain in the left side and sacrum, the development of an abdominal mass which disappeared in three weeks. Positive culture from uterus and cervix. ii. Patient thirty-five years, chills following labor, pain and swelling in calf of right leg followed by pains in left leg. Development of mass in the abdomen, posterior vaginal colpotomy releases 500 cc. of greenish pus. Convalescence very tedious. Gonorrhoeal ophthalmia of child cut short by suitable silver treatment. iii. Patient thirty years of age, four weeks after labor pain in the right knee is followed by infiltration and fluctuation of the joint. Thickening of the parametrium, gonococci in cervical and uterine cavities. iv. Woman of twenty-seven years, two weeks after labor gonorrhoeal endometritis, salpingitis and vaginitis, the entire vaginal mucous membrane being covered with a greenish-yellow exudate.

A case of unusual interest and significance is reported by Ashmead (*Am. Med. Jn.* JI. 20, 1901, 92,) of a woman who acquired gonorrhoea when four months pregnant. The child was delivered at term and was found to have healed opacities of both corneas. These were treated by iridectomy when the child was two years old.

A case of the writer's: A woman of thirty-three has a miscarriage at the sixth week. With a positive knowledge of gonorrhoeal urethritis in the husband, with the development of abscesses of the fingers and ankles of a three-year old child which contained the gonococcus in pure culture, and the positive history of gonorrhoeal vaginitis and urethritis in the patient herself,—it seems reasonable to presume that the

abortion was caused by gonorrheal endometritis and that the endocarditis which occurred in the second week of the mild puerperal fever which followed was due, indirectly at least, to the same organism.

Gonorrheal Peritonitis in the Female.

In discussing the mechanics of gonorrheal infection it has been made clear that women are much more liable to peritoneal complications than men. Infectious particles find their way to the peritoneum in the following ways, — directly through the lumen of the tubes; from rupture or distention of pus tubes; from mechanical perforation of gonorrheal uterus or tubes; from the bursting of extra-peritoneal abscesses wherever they may be, and from thrombo-phlebitis of sub-peritoneal vessels. Of all of these approaches the first and second are by far the most usual. Over-distention of gonorrheal tubes causes leakage, causing oft-repeated attacks of peritonitis which is localized if the amount exuded be small, and general if it be large. These attacks come on after prolonged or severe physical exertion, with extreme constipation, after accidental injuries whereby the abdominal and pelvic viscera are shaken, and at the menstrual period when pelvic congestion is the greatest. The later months of pregnancy bring increased tension on a distended pus tube and the violent muscular contractions of parturition may cause increased pressure on the tubes.

The mechanical abrasion or perforation of the uterus by instruments or curetté may be the cause of gonorrheal peritonitis, and operations for the relief of gonorrheal foci in the pelvis may assist the entrance of

the cocci to the peritoneal cavity as has been shown by two cases of Kossman. (Munch. med. Woch. Nos. 10 and 12.) The bursting of a sub-peritoneal abscess is a rare occurrence and may come from an abscessed lymph node under the abdominal or pelvic peritoneum, from a gonorrhoeal abscess of the kidney or from intramural encystment such as has been described by Ceppi. (Gaz. hebdom. de Sci. Med. Montpellier, May 29, 1901.)

The important features of gonorrhoeal peritonitis are illustrated by the following brief case reports:

Kelley. (Med. News, Oct. 19, 1895, 432.) Two cases of gonorrhoeal peritonitis from recent tubal rupture. Intestines agglutinated in all directions, — much free pus. Great prostration and rapid pulse. The effects on the system in gonorrhoeal peritonitis are by no means as great as those caused by streptococcus and staphylococcus infections. He considers these cases particularly favorable, the organism one of very low vitality, and does not drain them.

Richardson. (Ibid.) A case of septic fulminating gonorrhoeal peritonitis, a mass of swollen lymph glands just above Poupart's ligament containing gonorrhoeal pus furnishing the infecting focus. Operation did the patient no good, death resulting from general peritonitis.

Frank & Koehler. (Am. J. Obst. xlv, 3.) i. Woman of seventeen, uterine gonorrhoea from contaminated vaginal sponge, — chills, headache, rapid development of pyosalpinx. Operation shows pus in the left broad ligament; abdominal irrigation, drainage tube, abdominal wall sewn around it. Septic peritonitis develops in twenty-four hours with vomiting, delirium and death in seventy-two hours after the operation.

Post-mortem, one pint of pus found in the pelvis, entire peritoneum inflamed, intestinal peritoneum swollen, soft and ecchymosed, intestines agglutinated, free pus here and there in the peritoneal cavity among the intestinal coils. Pure culture of gonococci on blood serum, no other organisms.

ii. Woman of thirty-seven, colored, presenting symptoms of intestinal obstruction, is in a state of collapse, drugs and enemata fail to move bowels. Hard round mass on left side of abdomen resembling a fibroid tumor. No operation on account of poor condition of patient. One stool after eight minims of Croton oil with but slight improvement in patient's condition, the nausea and vomiting continues. Six days later pain appears in the left leg, there is anesthesia to the knee, foot is cold and a needle driven deeply into the leg cannot be felt, the limb becomes dry, discolored and fourteen days after the beginning of the attack is gangrenous. At this time the left parotid gland begins to swell, at first as a small nodule later increasing in size and fluctuating. Death three days later, nausea and vomiting persisting until the end. Post-mortem: Diffuse peritonitis, intense congestion of the intestines, free pus in the cavity. A large mass of thick jelly like purulent material surrounding the caput coli, filling the entire iliac region and proceeding from a large abscess of the right Fallopian tube. Uterus is studded with fibroids, some of them calcified and others edematous and suppurating. The tumor on the left side observed before operation and thought to be a fibroid, proves to be a tubal abscess containing a pint of pus. At the bifurcation of the left femoral vein is a large adherent clot completely

blocking the trunk as well as both branches, the vessels at this point showing the usual changes of endophlebitis. The parotid contains ten ounces of pus. Gonococci are found in the gangrenous tissues, the femorals, the parotid gland, the uterus and both tubes.

A case reported by Young (*op. cit.*) presents several important features. A girl of eighteen, with urethritis, vaginitis, salpingitis and general peritonitis, — all of gonorrhoeal origin. The low temperature of gonorrhoeal infections has already been noted and in this case the temperature was 98.6° F. and the pulse 100 and of good quality. Respirations 34, and a leucocytosis of 26,000. Operation shows the peritoneum greatly injected and uniformly covered with a layer of fibrin. The under surface of the liver, the spleen, stomach and pelvic viscera are deeply injected and thickly covered with exudate. Tubes and appendix covered with lymph and on pressure a drop of pus is seen at the tubal aperture. Both tubes removed, viscera sponged and lymph removed wherever possible, small drain leading to the pelvis is left in. Uneventful recovery. Cultures from fibrinous exudate from Douglas's pouch and under surface of liver show gonococci.

This case closely resembled perforative appendicitis but had the low pulse and temperature of a subacute process. It might be argued from this clinical history in which there is such extensive involvement of the abdominal and pelvic peritoneum, that the gonococcus was short lived and its toxin feeble, — a teaching insisted on by many of the earlier writers. The writer has been unable to find record of any abdominal case

with such extensive inflammation of the peritoneum due to other pyogenic organisms which has survived, and it would be expected that profound toxemia would result from so large an infected surface.

In a case reported by Penrose (Med. News, July 5, 1890, lvii, 16,) a man suffering from a particularly virulent gonorrhoeal urethritis infects his wife, who had been delivered of a healthy child one month before. Two days after the infection there is dysuria, swelling and pain in the vulva; three days later there is severe pelvic pain especially on the right side, free bleeding from the vagina, diarrhea and abdominal distention with great pain. Abdominal section shows the parietal peritoneum one-eighth inch thick, dark red and granular in appearance and bleeding easily; distention of all visible intestinal loops which show the same red granulations which bleed on the slightest pressure of sponges. Tubes the size of index finger, rigid, engorged and the fimbriae turgid, containing puriform fluid and thickened throughout by young celled deposit. Cocci but not gonococci are found in the fluid. In this case the recent gonorrhoeal infection and the red, easily bleeding granulations are strongly suggestive of the gonorrhoeal nature of the case, but the failure to find the organism in a case of such acute onset and such short duration might seem a cogent argument to the contrary, unless one shares in the view offered by some students of this problem, that gonotoxin alone is capable of producing intense reactions in susceptible individuals without the presence of the parent organism.

The following are references to cases of gonorrhoeal peritonitis of other observers:

Challan. (Gaz. di Torini, 1893, xi, 792.) Uncomplicated urethral gonorrhoea followed in eight days by suppurative peritonitis in which the gonococcus was the only organism found.

Mermet. (Ann. des Org. Gen.-Urin. 1893, 965.)

Cushing. (Jhn. Hop. Hospt. Bull. xiii, 247.) Twelve cases in which the peritonitis is dry or fibrous with but little pus or exudate.

Northup. (Arch. Ped. 1903, 910.) Two cases in girls.

Comby. (Arch. de Med. des Enfants, Vol. xiii.) Eight cases in girls of thirteen years and under.

Huber. (Bost. Med. & Surg. J. cxxi, 1899, 413.) A case suggestive of gonorrhoeal peritonitis but not positively proven such.

Hunner. (Jhn. Hop. Hospt. Bull. Oct. 1902, xiii, 247.) An interesting series of thirty-two cases. Seventeen operated on with thirteen recoveries. Of those not operated on eight recovered and six died, but all of these were moribund when presented for treatment. Characterizing these cases is the peculiar fact that they may be very sick at first but suddenly take a turn for the better. Their resemblance to appendicitis is very marked, but in this observer's opinion if it is possible to make a positive diagnosis of gonorrhoeal infection it is better not to operate but to wait for the favorable turn, in the natural course of the infection.

Additional bibliography:

- CHAPUT. Peritonite Blenorrhagique, Bull. de la Soc. Anat. de Paris, 1904, 9, 246.
- BRÖSE. Ueber der diffuse gonor. Periton. Berl. klin. Woch. xxxiii, 779.

- v. LEYDEN. Diffuse eiterig-fibrinöse Periton. mit Gonok. befund. Mittheilung, Verein f. inn. Med. 27, xi, 1899.
- DÖDERLEIN. Allgemeine Periton. Viet's Handbuch. iii, 2, p. 840.
- MUSCATELLO. La Peritonite gon. dif. Il Policlinico, Aug. 1901.
- VON BRUNN. Cent. f. allgem. Path. u. path. Anat. xii, No. 1.

Gonorrhœa as a Cause of Sterility in the Female.

Conception depends upon the proper development, migration and arrest of the male and female gametes. The obstacles to the development of the microgamete have been described in the pathology of orchitis, the proliferating epithelium of sperm cells being choked by connective tissue or destroyed by suppuration. In the female sterility may be due to the imperfect development of the ovule, obstruction to its progress to the uterus, or unsuitable environment in the uterus should the fertilized ovum reach the endometrium. Gonorrhœa is capable of causing all of these states. Gonorrhœal disease of the ovary destroys germinating protoplasm, peri-ovaritis or peri-salpingitis prevents an ovum from reaching the finbriated ends of the tubes. But should an ovum become matured, it cannot pass through a Fallopian tube destitute of epithelium, perhaps filled with pus, agglutinated by inflammatory connective tissue or distorted by peritoneal adhesions. But should a matured or fertilized ovum reach the uterine cavity, there to find a condition of gonorrhœal endometritis, the environment is manifestly unsuited to its development or life, it is speedily invaded by various organisms, for the infection in the uterus is nearly always mixed, and pregnancy ceases almost as soon as it is begun. Pregnancy is quite possible with gonorrhœal disease of the urethra, vagina, and possibly

of the tubes and ovaries, if the process does not inhibit the functions necessary to the condition, but impossible if there is endometritis from gonorrhœa.

The important question of operations on cases of gonorrhœal affections of the abdominal and pelvic viscera is quite germane to the subject matter of this essay. Latent and subacute gonorrhœa produce generations which are not only viable, but are occasionally virulent and capable of producing a toxin which is quite unparalleled by any produced in vitro. And since it has been known that gonorrhœal pus from the tubes is quite capable of producing fulminating peritonitis, gynecologists are operating with great caution in cases of gonorrhœal infection of the pelvis. Kronig (*op. cit.*) lays great stress upon this point and urges the probability of operative interference making bad matters worse in such cases. In the writer's opinion the point of the greatest importance in this question is the period of time which has elapsed since the onset of tubal symptoms. The greater the lapse, the more likely are the contents to be sterile, a thing which is true of all suppurative processes, but particularly of gonorrhœal. In the case of pus tubes, operation should be deferred until the subsidence of all acute symptoms and the cases of speedy death reported by Hunner, Kronig, Koehler and others must be taken as testimony of great weight in deciding this question. In the event of general or localized peritonitis which offer the physical signs of pus accumulations, the best surgical thought still demands that an operation be made to liberate septic material.

As a cause of death in pelvic and abdominal affections it must be again admitted that the streptococcus

surpasses the gonococcus in activity. Robb (Am. Gyn. Trans. 1904,) shows this fact by startling figures. He reviews 742 cases of abdominal section in which there was a mortality of 3.45%. Of these nineteen were proven streptococcic of which seven died, a mortality of 36.8%.

The question of the advisability of operations on cases of gonorrhoeal infection and the comparisons already made with the deportment of the streptococcus pyogenes make it necessary to assemble those points of differential diagnosis which are warranted by the present state of our recently acquired knowledge of pelvic inflammations.

Streptococcus.

Gonococcus.

History. No venereal disease.	Of urethritis, vaginitis or vulvitis with pus from the vulva.
Temperature. High with wide excursions.	Usually under 101° F. and of low range.
Pulse. Corresponding with the high temperature.	Often under 100.
Leucocytosis. High, to 35,000.	Low. 13,000 or under.
Pyosalpinx. Not common.	Usual.
Adhesions. Many and firm.	Not prone to adhesions.
Palpation. Boardy dense feel.	Boggy and spongy.
Lesions. Asymmetrical.	Bilateral.
Vaginal discharge. Scanty.	Profuse.

VII.

CONCLUSIONS.

Gonorrhœa Predisposing to Genito-Urinage Tuberculosis.

THE important question of gonorrhœa as a possible element in the etiology of tuberculosis and malignant tumors of the genito-urinary organs is suggested by the well-known fact that these diseases are frequently engrafted upon damaged tissues. An inflamed respiratory or intestinal tract, crushed periosteum, broken bone, previously inflamed glands, — these are the conditions which tuberculosis finds most favorable for its development. Now we have in gonorrhœa and its complications, together with the operations and instrumentation which seem necessary in its treatment, the most common causes of lesions of the genito-urinary tracts of both sexes.

Genito-urinary tuberculosis, however, is not a common affection. In 1,000 autopsies recorded by Osler, the kidneys were tubercular in but thirty-two and the generative organs in but eight. In 8,873 surgical cases in the Wurtzburg clinic, 1,287 were tuberculous, but of these only twenty were of the genito-urinary organs. In 2,500 autopsies, on women in the Dresdener Krankenhaus, vesical tuberculosis was observed but four times.

Bearing in mind the very great frequency of gonorrhoea it must be concluded that gonorrhoeal urethritis does not predispose to tuberculosis to any extent. Occasionally a case is observed in which gonorrhoeal urethritis precipitates a tuberculous orchitis early in its course. Such a combination is usually characterized by great severity of both infections and very rapid infiltration followed by extensive suppuration and destruction of tissue. They are explained by the theory that a subacute or latent tuberculosis is stirred into activity by the gonococcus, a theory which is greatly strengthened by the recent finding of tubercle bacilli in apparently healthy organs.

In the same way it may be said that the lesions remaining after gonorrhoea are not likely to be invaded by carcinoma, for in records of 7,000 autopsies Hasenclever found but forty cases of vesical carcinoma, and in the records of the Pathological Institute in Munich, Zasnch could find but fourteen. Carcinoma of the prostate, too, is so rare an affection that one is unable to establish any relation between occasional cases and gonorrhoeal disease.

From this review of cases known to have the gonococcus for their chief etiological factor, and from inquiry into the various circumstances which so frequently attend its presence it must be evident that it must be accorded a position of great importance in the etiology of disease. And, although a complete study of recent literature is necessary to fully appreciate the number and variety of lesions this bacterium may occasion, the more novel and important may be summed up in the following conclusions:—

Gonorrhœal infection may be one of the most formidable of bacterial invasions.

The virulence of the gonococcus varies within wide limits and reaches its maximum by prolonged incubation in the human host.

Nearly all parts of the human organism have been invaded by the gonococcus.

It is an occasional cause of death by causing general peritonitis or general involvement by distribution through the circulation.

Its direct effects are equalled and perhaps exceeded by its lesions offering opportunity for the ingress of other bacteria.

These scientific findings are of great value to the medical profession, the sociologist and all others who seek the amelioration of social evils.

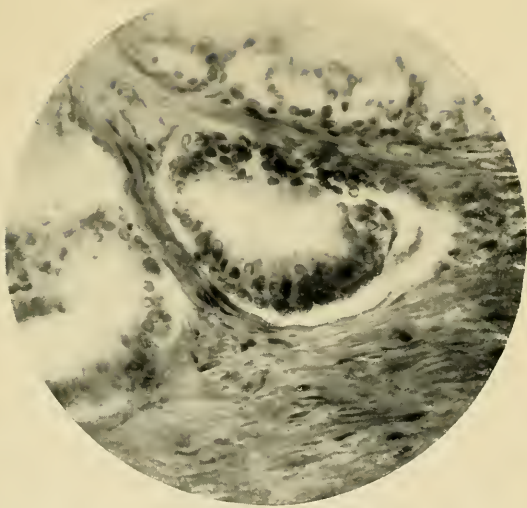


FIG. 1.—Typical normal glandular unit of prostate showing the columnar epithelium in the fibromuscular stroma. $\times 600$.

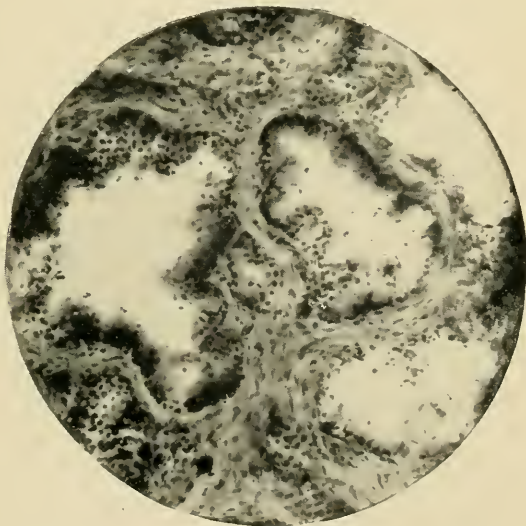


FIG. 2.—Representing section of prostate in the first stage of gonorrheal invasion. The outline of the epithelium is lost; there is infiltration with small round cells, which in places have replaced the epithelium. Even the connective tissue framework is becoming invaded. $\times 250$.

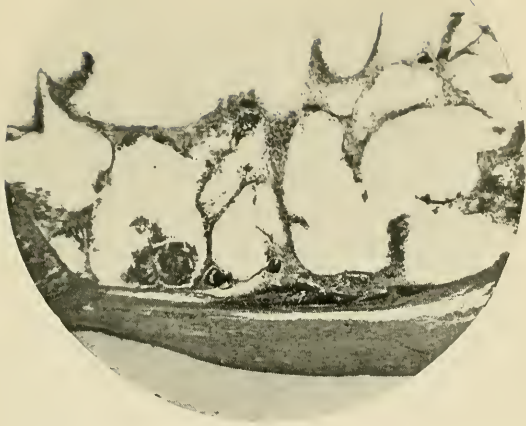

FIG. 3.—Showing the last stages of gonorrheal prostatitis with abscess formation. There is complete obliteration of structure, and there remains only the framework to which pus corpuscles are clinging. The capsule is not affected and has limited the process. X 90.

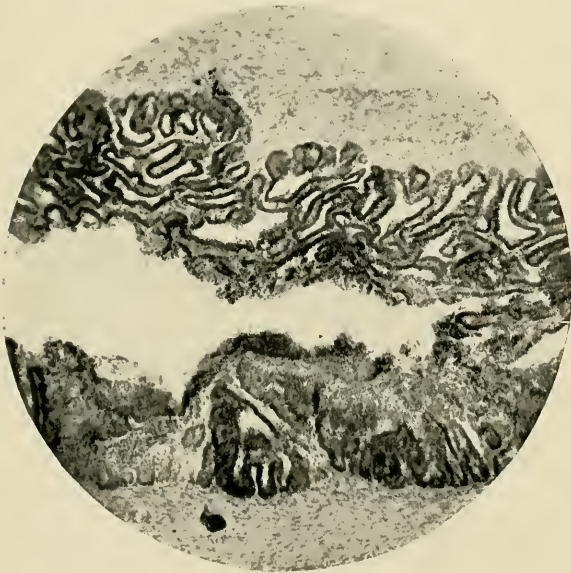

FIG. 4.—Section of seminal vesicle in gonorrheal inflammation. In the upper part of the field the epithelium is fairly normal and shows no irregularities with this low power. Just beneath this it will be seen that invasion has begun, and a hand lens shows the disintegration and loss of contour. On the lower side of the lumen a more advanced stage still is illustrated,—the structure is completely obliterated and at the right the firm mass is beginning to break away. X 40.

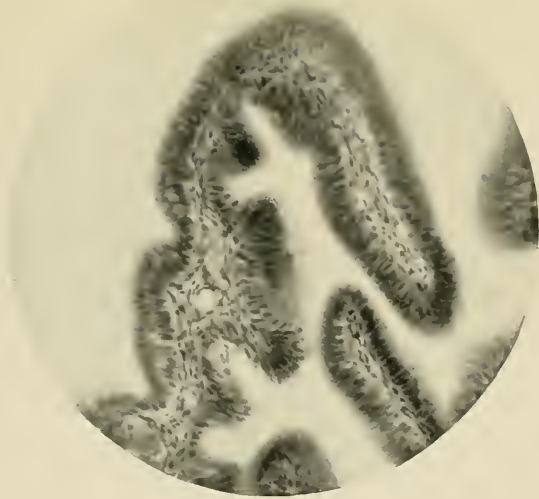


FIG. 5.—Normal fold of mucous membrane of Fallopian tube showing relations of stroma and epithelium. $\times 250$.

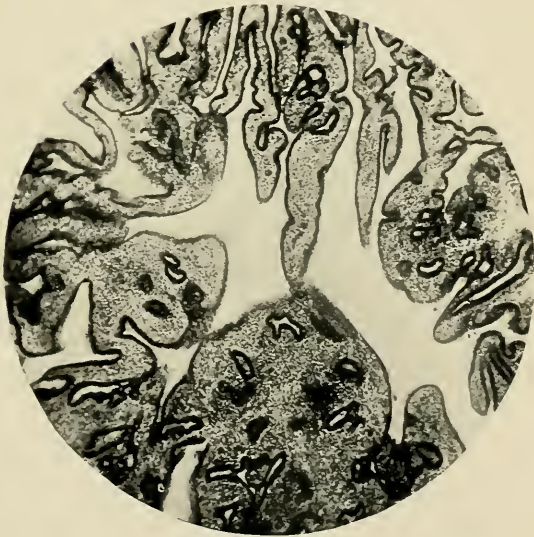

FIG. 6.—Section of Fallopian tube in the first stage of gonorrheal inflammation. Some of the folds are normal or only slightly swollen, others show beginning infiltration. In the lower part of the field is an example of a process in a state of very great distension. $\times 100$.

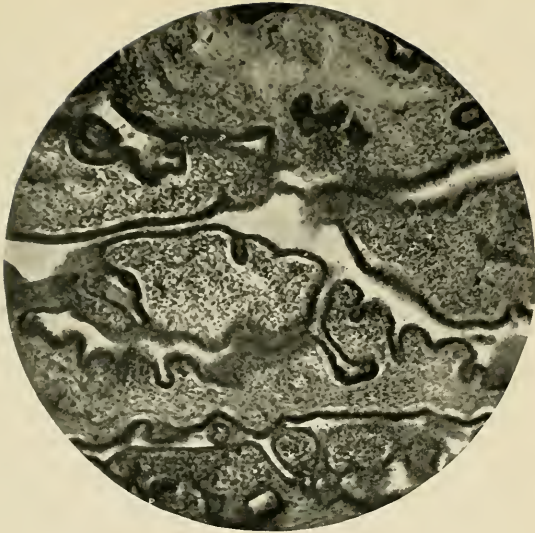

FIG. 7.—Showing a still more advanced state of gonorrheal infiltration. The folds are matted together and in some places their structure is entirely obliterated. $\times 120$.

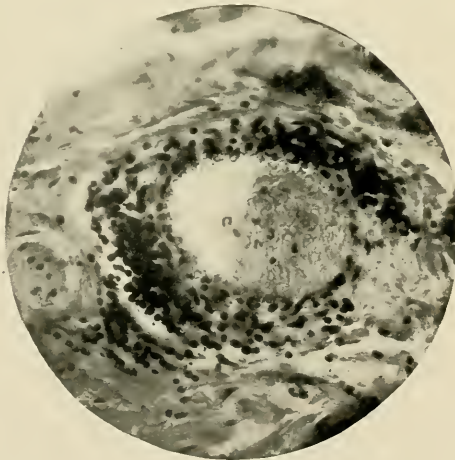


FIG. 8.—Section of vein in the substance of gonorrheal Fallopian tube. The picture is one of intense vasculitis, the walls being so infiltrated that their structure is obscured. Leucocytes are seen in the lumen, and with a hand lens it is seen that the vessel is in the act of distributing septic particles to the circulation. $\times 500$.

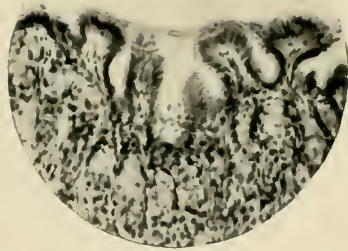


FIG. 9.—Section from frog's stomach into which 1-100 silver nitrate solution has been injected and representing the normal mucosa. X 100.

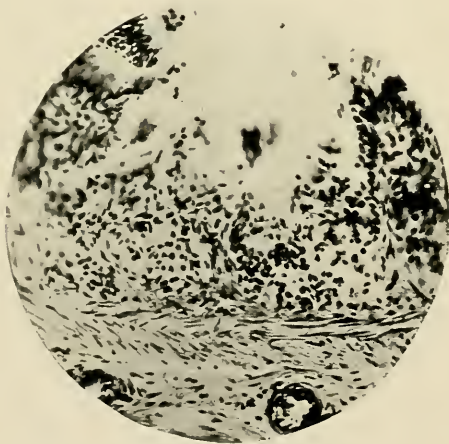


FIG. 10.—Section of stomach of frog showing the result of injecting 1-10 silver nitrate solution. At this point there is destruction of villi and infiltration of the vestiges, but the sub-mucous tissue is unaffected. X 250.

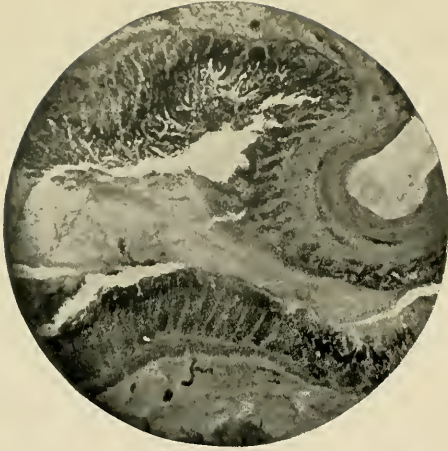

FIG. 11.—Section of stomach of frog which has been given 1-2000 solution of corrosive sublimate. The contour of mucous folds is obliterated; there is desquamation of epithelium and tenacious mucous has agglutinated the opposite walls. In other sections the entire mucous membrane is in some places lacking. X 60.

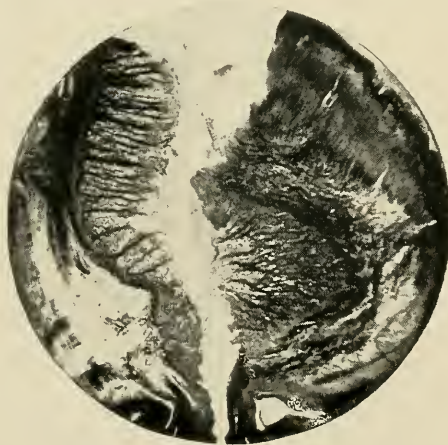

FIG. 12.— Same as Fig. 11, but stained with Mallory's connective tissue stain which is nearly opaque to chemical rays. X 50.

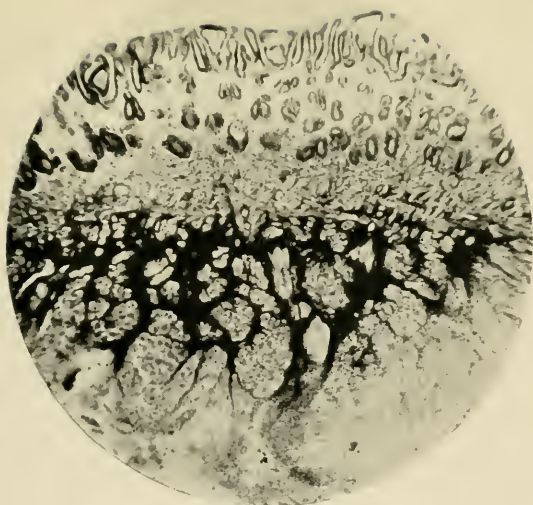


FIG. 13.— Section of tongue of frog into which a 1-2000 solution of corrosive sublimate has been injected. Stained with Mallory's connective tissue stain and showing a very marked increase of that tissue. These experiments suggest the possibility that this chemical may contribute to the etiology of stricture, epididymitis and other complications. X 80.

1901

